

CLINICAL REPORT

Delay in the Histopathologic Diagnosis of Mycosis Fungoides

Anne G. SKOV and Robert GNIADDECKI

Department of Dermatology, University of Copenhagen, Bispebjerg Hospital, Copenhagen, Denmark

The diagnosis of mycosis fungoides (MF) is difficult in early stages and is based on a combination of clinical findings and histopathologic criteria. The aim of this study was to assess the diagnostic delay in MF and to investigate the rationale for multiple biopsies in a single-centre, retrospective study of 157 patients with MF. The first biopsy was diagnostic for MF in 25% of cases. The median diagnostic delay was 2.3 years and depended on whether the diagnosis was established after one or multiple biopsies. The chance of a biopsy resulting in a diagnosis of MF was 25% irrespective of the number of the biopsy in the sequence. There was a significant diagnostic delay, especially in patients in whom the initial biopsy was not specific. Sampling error and unnecessary postponement of subsequent biopsies are likely factors and therefore multiple biopsies should be considered in patients with skin lesions suggesting MF. Key words: mycosis fungoides; diagnostic delay; cutaneous T-cell lymphoma.

Accepted Sep 16, 2014; Epub ahead of print Sep 17, 2014

Acta Derm Venereol 2015; 95: 472–475.

Anne Gulddammer Skov, Department of Dermatology, Bispebjerg Hospital, Bispebjerg bakke 23, DK-2400 Copenhagen, Denmark. E-mail: annegskov@hotmail.com

Early mycosis fungoides (MF) is one of the most challenging diagnoses in clinical dermatology (1–4). Histopathology is not specific in a significant number of cases and in most centres the diagnosis is established on the basis of expert assessment of the characteristics of skin lesions in combination with disease history, histopathology, immunophenotypic and molecular (T-cell receptor [TCR] monoclonality) studies. Lack of the diagnostic gold standard and insufficient discriminatory power of the current approach must necessarily lead to diagnostic delays. Since MF is a malignant disease with a lifetime progression risk of 34% and mortality of 26% (5) diagnostic delay impeding the introduction of optimal therapy raises significant medico-legal questions.

In spite of the fact that diagnostic problems in early MF are well-known for the clinicians (5) there are surprisingly few studies addressing the diagnostic delay and the precision of current diagnostic approaches. In 2005 the International Society for Cutaneous Lympho-

ma (ISCL) proposed a consensus diagnostic algorithm based on clinical, histological, molecular biological and immunopathological criteria (5). The diagnostic algorithm applies to cases when the patient presents with suspicious skin lesions (persistent or progressive skin patches or plaques) and the biopsy reveals superficial lymphocytic infiltrate. Diagnosis of MF requires at least 4 points which are derived from additional clinical symptoms: *i*) localisation of lesions on non-sun exposed skin, size and shape variation, poikiloderma; *ii*) histopathology (epidermotropism without spongiosis, lymphocytic atypia); *iii*) the presence of TCR monoclonality, and *iv*) immunopathologic findings (CD2, CD3, CD5, CD7 positivity and aberrant expression). However, ISCL criteria have a number of drawbacks, which preclude their wider use in the everyday clinical practice. Rigid application of the ISCL algorithm would allow making the diagnosis of early MF without typical histopathology. However, many experts will be reluctant to make the diagnosis in the early stage based primarily on immunohistochemistry and TCR rearrangement (6). Some histopathologic features such as basal layer vacuolisation, lymphocyte alignment along the basal membrane or dermal fibrosis which several dermatopathology experts consider highly predictive, have not been included. In contrast, lymphocytic atypia listed in the ISCL criteria is a variable and subjective feature of a dubious independent value in early MF (6, 7). Lastly, the ISCL criteria are based on expert consensus and have never been subjected to rigorous, prospective evaluation for specificity and sensitivity.

In this retrospective analysis of 157 patients diagnosed with MF in a single centre with expertise in cutaneous lymphomas we provide evidence of a significant delay in the diagnosis of early disease. Furthermore, we document the need of multiple biopsies in a significant proportion of patients with an initially unspecific histopathology, which has been advocated by some experts (6) but is not implemented in the current ISCL guidelines.

MATERIALS AND METHODS

Patients

This database study is based on a cohort of Danish patients with MF who were treated in the tertiary referral centre for cutaneous lymphomas at the Department of Dermatology, Bispebjerg Hospital, Copenhagen, Denmark between 1st January 2000 and

1st July 2012. These patients were prospectively registered in a clinical database (CLDbase – The Cutaneous Lymphoma Database). Missing data were collected by clinical interview of the patients or from the patient files. All patients included in this study had an unequivocal diagnosis of MF established either by unequivocal histopathology together with the presence of typical cutaneous lesions, or by longitudinal observation and documentation of the development of thick plaques and/or tumours. Typical cutaneous lesions are erythematous skin lesions (patches, plaques and rarely tumours) located on sun-protected areas, although any skin site may be involved. In early MF patches and plaques are sometimes accompanied by poikiloderma. The histopathologic data were obtained from the national Danish pathology registry (Patobanken), which records all material sent to the departments of pathology in Denmark. A conclusive MF biopsy was defined as a biopsy described by an experienced dermatopathologist as a definite MF. The description documented as a minimum the lymphocytic T-cell infiltrate (CD3⁺CD4⁺ or CD3⁺CD8⁺) with epidermotropism or Pautrier microabscesses. Exclusion criteria were: another specific diagnosis, non-conclusive biopsy or a biopsy compatible but not diagnostic for MF in patients with a too short observation time allowing for the unequivocal diagnosis on the clinical grounds alone. We identified 157 patients (93 males (59.2%) and 64 females (40.8%)). The mean age at onset of MF was 58 years (range 23–92 years); 146 patients had classic MF and 11 had a folliculotropic variant. No cases of Sézary syndrome were included.

Definition of the endpoints and data analysis

Diagnostic delay was defined as the time from onset of disease until an unequivocal histopathologic diagnosis of MF. For patients with a history of symptoms of disease predating the conclusive or MF compatible skin biopsy the date of onset of symptoms, as recalled by the patient, was used. The recalled date of symptom onset could predate the first registration in CLDbase. If the symptomatic onset of disease was later than a conclusive or MF compatible skin biopsy, the date of onset was defined as the date of the biopsy. The dates for biopsies were collected from pathology database (Patobanken). All biopsies were paraffin embedded. The size of all biopsies was 3–4 mm in diameter. Biopsies taken at the same occasion were counted as one biopsy. All statistical analyses were performed using SPSS version 19.0.

RESULTS

Number of biopsies necessary for the conclusive diagnosis

By definition, all 157 patients had a minimum of one biopsy. The median time from onset of disease until

last recorded biopsy was 11.6 years (mean 13.3, range 0.52–42.0 years).

In 111 patients (70.7%) a histopathologic diagnosis of MF could be established during the follow-up period: in 39 patients (24.8%) at the time of their first biopsy and 72 patients (45.9%) on subsequent biopsies. In 46 patients (29.3%) a histopathologic diagnosis of MF was never established and in these cases MF was diagnosed clinically (persistent, evolving thick plaques or tumours). The 3 most frequent tentative histopathologic diagnoses in early MF with unspecific findings were dermatitis, inflammation and the superficial lymphocytic infiltrate compatible with but not diagnostic for MF (Fig. 1).

Among the 72 patients with more than one biopsy before the diagnosis, 27 patients (37.5%) had 2 biopsies and 16 patients (22.2%) had 3 biopsies. The mean number of biopsies was 2.89 (range 1–12). The probability of obtaining a conclusive diagnosis of MF on a single biopsy (calculated as the number of positive biopsies divided by the total number of biopsies within the sequence number) was independent of the number of previous negative biopsies and was approximately 25%. The cumulative probability of a positive biopsy as a function of biopsy sequence number had a predicted log-linear cumulative Poisson distribution shape (Fig. 2).

Diagnostic delay

The median time from onset of disease until the first biopsy was performed was 0.08 years (mean 2.16, range 0.00–23.0 years) (Fig. 3). In the 39 patients with the histopathologic diagnosis of MF established on the first biopsy the median diagnostic delay was 0.38 years (mean 2.60, range 0.00–21.3 years).

The median time from onset of disease until a histopathologic diagnosis of MF (conclusive biopsy) was 2.27 years (mean 5.48, range 0.00–29.9 years) (Fig. 3). In 72 patients the histopathologic diagnosis of MF was established on a later biopsy with a diagnostic delay of 4.34 years (mean 7.02, range 0.05–29.9 years). The median diagnostic delay was 0.97 years (mean 2.99, range 0.05–13.7 years) for 10 patients initially diagnosed with MF obs. pro., 3.87 years (mean 6.89, range 0.23–22.5

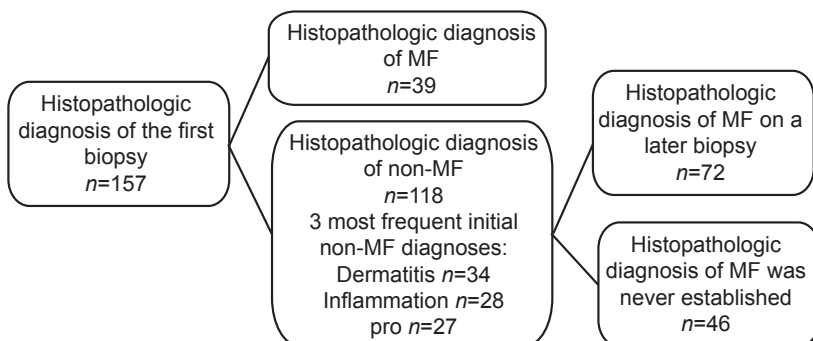


Fig. 1. Flowchart of the skin biopsies performed from the 157 patients eventually diagnosed with mycosis fungoides (MF) during the follow-up between 2000–2012.

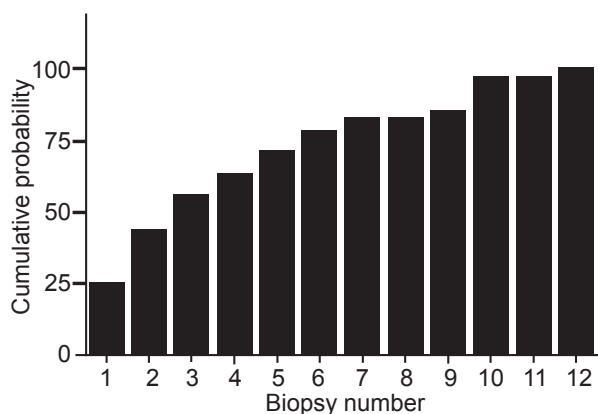


Fig. 2. Cumulative probability of a positive biopsy as a function of biopsy sequence number.

years) for those 21 patients with initial dermatitis and 4.40 years (mean 6.96, range 0.27–25.2 years) for 22 patients diagnosed with inflammation. There was no difference in the diagnostic delay between the patients with classic MF and the folliculotropic MF.

DISCUSSION

In this retrospective study comprising 157 patients with MF, we found a median diagnostic delay of 2.3 years between the occurrence of skin symptoms and the histopathologic confirmation of MF. Data in Fig. 3 indicate that this delay was primarily due to a failure to obtain a specific histopathological diagnosis rather than a delay in taking a biopsy. In the 25% of patients where the first taken biopsy showed unequivocal MF the median diagnostic delay was only 5 months versus 4.3 years in the patients in whom multiple biopsies were required to establish the diagnosis. Our results are in agreement with the experience in other centres. Suzuki et al. (8) and Kim et al. (9) studied patients with MF and Sézary syndrome and found a median symptom duration until diagnosis of 4 years (range 1 month–66 years) and 4.2 years (range 0.1–70.1 years), respectively. Quaglino et al. (10) and van Doorn et al. (11) detected a median time from the onset of disease to the diagnosis of 2–4 years (range 1 month–> 50 years).

One important conclusion from our study is that multiple biopsies are necessary to establish the diagnosis in most patients and it is likely that the reluctance to take several biopsies contributes to diagnostic delay. Usually, the patients in whom the diagnosis of CTCL is suspected are seen in the outpatient clinic every 3–6 months. As shown in Fig. 2 the cumulative probability of the diagnostic biopsy increases steeply for the first 5 biopsies. Interestingly, the chance of diagnostic biopsy is approximately 25% irrespectively of the number of the biopsy in sequence. This may suggest that false negative biopsies represent sampling error rather than inherently nonspecific character of histopathological changes in early MF.

The retrospective design of this study has inherent limitations. Ill-defined histopathologic diagnoses may reflect personal bias of the relatively few dermatopathologists who were responsible for the final diagnosis. In this regard we found it surprising that approximately 30% of patients never had a diagnostic biopsy. This may reflect the tendency to stringent histopathologic diagnosis of MF in our centre (the low sensitivity, high specificity) but may also reflect lack of motivation of the attending physician and the patient to undertake multiple biopsies in a situation when the clinical diagnosis is obvious and the histopathology compatible with MF. Topical treatments (e.g. topical steroids) may in theory mask the typical histopathological features of MF and cause a diagnostic delay. Finally, the onset of the disease was established retrospectively in most of the cases, which may exaggerate diagnostic delay due to a recall bias. Lastly, we did not critically assess the added value of TCR rearrangement studies and immunohistochemistry (as suggested in the ISCL algorithm) in our population. The main reason was that these examinations were not routinely done in all patients and the methods changed several times within the last 10 years making comparison of the data very difficult.

In summary, our study underscores the clinical need for the development of better diagnostic algorithms in early MF. The 2–4 year median delay in the diagnosis may be unacceptable in many patients causing an unnecessary postponement of the optimal therapy. A se-

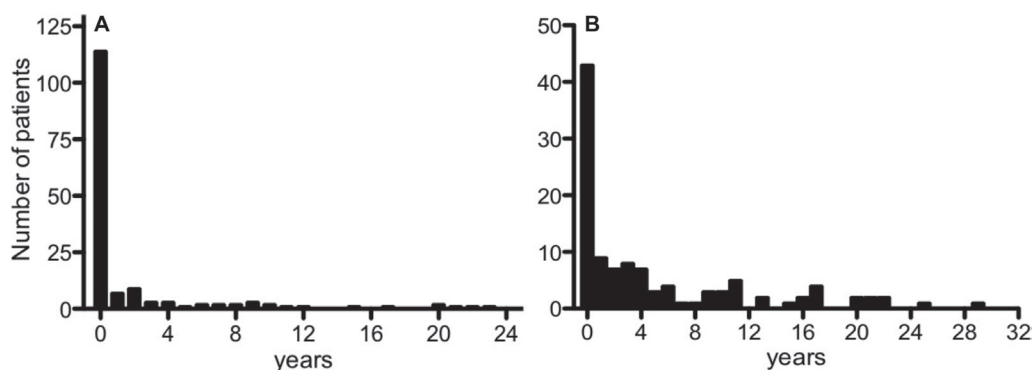


Fig. 3. Histogram of the time from onset of disease to the first biopsy (A) and conclusive biopsy (B).

cond important finding is a diagnostic value of repeated biopsies. Our data suggest that the chance to obtain a conclusive biopsy was 25% irrespective of the number of the biopsy in sequence and in case of an unspecific histopathology the patient should be re-biopsied without delay. Our data uncover potentially interesting areas for future studies: the need for critical assessment of the specificity and sensitivity of the proposed ISCL algorithm, sampling error associated with random skin biopsies and the added value of immunophenotyping and TCR monoclonality in early diagnosis of MF.

ACKNOWLEDGEMENTS

Naomi Rosenberg and Ida Tanentsapf who entered many data into the database are greatly acknowledged.

The authors declare no conflict of interest.

REFERENCES

1. Hwang ST, Janik JE, Jaffe ES, Wilson WH. Mycosis fungoides and Sezary syndrome. *Lancet* 2008; 371: 945–957.
2. Wilcox RA. Cutaneous T-cell lymphoma: 2011 update on diagnosis, risk-stratification, and management. *Am J Hematol* 2011; 86: 928–948.
3. Willemze R, Jaffe ES, Burg G, Cerroni L, Berti E, Swerdlow SH, et al. WHO-EORTC classification for cutaneous lymphomas. *Blood* 2005; 105: 3768–3785.
4. Zinzani PL, Ferreri AJ, Cerroni L. Mycosis fungoides. *Crit Rev Oncol Hematol* 2008; 65: 172–182.
5. Pimpinelli N, Olsen EA, Santucci M, Vonderheid E, Haeflner AC, Stevens S, et al. Defining early mycosis fungoides. *J Am Acad Dermatol* 2005; 53: 1053–1063.
6. Ferrara G, Di BA, Zalaudek I, Argenziano G, Cerroni L. Regarding the algorithm for the diagnosis of early mycosis fungoides proposed by the International Society for Cutaneous Lymphomas: suggestions from routine histopathology practice. *J Cutan Pathol* 2008; 35: 549–553.
7. Yeh YA, Hudson AR, Prieto VG, Shea CR, Smoller BR. Reassessment of lymphocytic atypia in the diagnosis of mycosis fungoides. *Mod Pathol* 2001; 14: 285–288.
8. Suzuki SY, Ito K, Ito M, Kawai K. Prognosis of 100 Japanese patients with mycosis fungoides and Sezary syndrome. *J Dermatol Sci* 2010; 57: 37–43.
9. Kim YH, Liu HL, Mraz-Gernhard S, Varghese A, Hoppe RT. Long-term outcome of 525 patients with mycosis fungoides and Sezary syndrome: clinical prognostic factors and risk for disease progression. *Arch Dermatol* 2003; 139: 857–866.
10. Quaglino P, Pimpinelli N, Berti E, Calzavara-Pinton P, Alfonso LG, Rupoli S, et al. Time course, clinical pathways, and long-term hazards risk trends of disease progression in patients with classic mycosis fungoides: A multicenter, retrospective follow-up study from the Italian Group of Cutaneous Lymphomas. *Cancer* 2012; 118: 5830–5839.
11. van Doorn R, Van Haselen CW, van Voorst Vader PC, Geerts ML, Heule F, de Rie M, et al. Mycosis fungoides: disease evolution and prognosis of 309 Dutch patients. *Arch Dermatol* 2000; 136: 504–510.