

## INVESTIGATIVE REPORT

# Eight Novel Mutations Confirm the Role of *AAGAB* in Punctate Palmoplantar Keratoderma Type 1 (Buschke-Fischer-Brauer) and Show Broad Phenotypic Variability

Kathrin A. GIEHL<sup>1,2</sup>, Thomas HERZINGER<sup>2</sup>, Hans WOLFF<sup>1,2</sup>, Miklós SÁRDY<sup>1,2</sup>, Tanja VON BRAUNMÜHL<sup>2</sup>, Valérie DEKEULE-NEER<sup>3</sup>, Yves SZNAJER<sup>4</sup>, Dominique TENNSTEDT<sup>3</sup>, Pascaline BOES<sup>4</sup>, Stefan RAPPRICH<sup>5</sup>, Nicola WAGNER<sup>5</sup>, Regina C. BETZ<sup>6</sup>, Markus BRAUN-FALCO<sup>2</sup>, Tim STROM<sup>7</sup>, Thomas RUZICKA<sup>2</sup> and Gertrud N. ECKSTEIN<sup>7</sup>

<sup>1</sup>Center for Rare and Genetic Skin Diseases, Department of Dermatology, <sup>2</sup>Department of Dermatology, Ludwig-Maximilian University, Munich, Germany, <sup>3</sup>Department of Dermatology, <sup>4</sup>Center for Human Genetics, Cliniques Universitaires St Luc, UCL, Brussels, Belgium, <sup>5</sup>Department of Dermatology, Klinikum Darmstadt, Darmstadt, <sup>6</sup>Institute of Human Genetics, University of Bonn, Bonn, and <sup>7</sup>Institute of Human Genetics, Helmholtz Zentrum München, German Research Center for Environmental Health, Neuherberg, Germany

**Punctate palmoplantar keratoderma (PPKP1; Buschke-Fischer-Brauer) is a rare autosomal dominant inherited skin disease characterized by multiple hyperkeratotic papules involving the palms and soles. Mutations have been found at 2 loci, on chromosomes 15q22–15q24 and 8q24.13–8q24.21. We recently identified mutations in 3 families, in the *AAGAB* gene on 15q, which encodes the alpha- and gamma-adaptin-binding protein p34. The current study examined 14 additional families, comprising a total of 26 affected individuals and identified 8 novel mutations in 9 families. In one family a mutation representing a known SNP that was present only in the affected individuals was found, and in 4 other families, previously reported mutations were found (1, 2). These results confirm the role of *AAGAB* in PPKP1. Our findings suggest that there is no correlation with age, but with mechanical factors. No additional obvious genotype–phenotype correlation was observed, even when comparing different types of mutations. Rather, identical genotypes presented a very broad interfamilial and intrafamilial variability of phenotypes. *Key words: punctate palmoplantar keratoderma; PPKP1; AAGAB; phenotype-genotype correlation.***

Accepted Nov 24, 2015; Epub ahead of print Nov 26, 2015

Acta Derm Venereol 2016; 96: 468–472.

Kathrin Giehl, Center for Rare and Genetic Skin Diseases, Department of Dermatology, Ludwig-Maximilian-University Munich, Frauenlobstr. 9-11, DE-80337 Munich, Germany. E-mail: kathrin.giehl@med.uni-muenchen.de

Punctate palmoplantar keratoderma type I (PPKP1; OMIM #148600), also called keratosis punctata palmoplantaris Buschke-Fischer-Brauer, was first described in 1910 by Buschke & Fischer (3) and Brauer (4). It is mostly an autosomal dominant inherited disease, but sporadic cases have also been described (5). It is characterized by multiple hyperkeratotic papules with central indentation irregularly distributed on the palms and soles, as opposed

to the mostly diffuse hyperkeratinization observed in other palmoplantar keratodermas (6, 7). In mechanically irritated areas, confluent plaques can be found. The lesions usually develop in early adolescence, but can also occur later in life (5). The incidence of PPKP1 has not been extensively evaluated, but has been estimated at 1.17 per 100,000 inhabitants in Croatia (8). There have been reports in which punctate palmoplantar keratoderma was associated with the development of both early- and late-onset malignancies, including squamous cell carcinomas (9–11). Possible treatments include keratolytic ointments, mechanical reduction of the hyperkeratoses, and systemic retinoids.

Recently, the identification of pathogenic mutations in *AAGAB*, which encodes the alpha- and gamma-adaptin-binding protein p34, was described for the first time by the authors of the current paper and others (1, 12), after previous reports had mapped the critical region to chromosomes 15 and 8 (13–18).

The current study examined 14 additional families for mutations in *AAGAB*, and studied a possible genotype–phenotype relationship and the phenotypic variability within and between the families.

## MATERIALS AND METHODS

### *Patients*

All family members gave informed consent prior to participation. The study was approved by the institutional review board of the Ludwig-Maximilian University of Munich, and adhered to the principles of the Declaration of Helsinki. Blood samples were taken from all 33 investigated individuals. To establish the phenotype, the palms and soles of all individuals participating in this study were clinically assessed (mild: < 10 papules on hands and feet; moderate: < 50 papules on hands and feet; severe: ≥ 50 papules on hands and feet, elevated lesions, confluent hyperkeratosis). All patients were asked to report a subjective severity score of 0–10 describing the pain caused by the skin lesions.

### *Mutation analysis*

PCR primers were used as described earlier (1). The coding region and the exon-intron junctions were sequenced by the Sanger method

using Big Dye Terminator cycle sequencing kit v3.1 (Applied Biosystems/Life Technologies, Grand Island, NY, USA) and analysed on an ABI 3730 Genetic Analyzer (Applied Biosystems). Sequences were analysed for mutations with the Staden Package 2.0 (open source sequence analysis tool; <http://staden.sourceforge.net>). Segregation analysis was performed on all available family members to confirm co-segregation with the phenotype in all pedigrees.

*Computational analysis*

Splice site variants were analysed *in silico* with CRYP-SKIP 9 (<http://cryp-skip.img.cas.cz/>) to predict the probability of exon skipping or cryptic splice site activation of the mutated allele. The other changes were studied using different programs to predict whether variants are deleterious. PolyPhen-2 (<http://genetics.bwh.harvard.edu/pph2/bgi.shtml>) classifies an amino acid substitution as probably damaging, possibly damaging, benign, or of unknown significance. SIFT (<http://sift.jcvi.org/>) predicts whether a change is tolerated or damaging. For mutations affecting the start codon, the ORF Finder (Open Reading Frame Finder; <http://www.ncbi.nlm.nih.gov/projects/gorf/>) from the US National Center for Biotechnology Information (NCBI) was used to check if there was an alternative open reading frame with sequence similarity to the AAGAB open reading frame. This tool identifies all open reading frames using the standard or alternative genetic codes.

RESULTS

Mutation analysis of AAGAB in 26 affected individuals with palmoplantar keratoderma from 14 families revealed 12 different mutations, 8 of which are novel. These changes include 3 mutations affecting the translation initiation site, 1 missense mutation, 3 frameshift mutations, 2 splice site mutations, and 3 nonsense mutations (Table S1<sup>1</sup>).

Segregation analysis was performed in all cases when related individuals joined the study, and co-segregation of the mutation with the disease was observed in all available families (Fig. S1<sup>1</sup>).

Keratoses on the soles were more severe than those on the palms, especially at points of pressure. Phenotypic variability could be observed between, as well as within, families (Fig. 1). Of the 26 affected individuals, 17 were women and 9 were men. The mean onset of disease was 18.2 years. A detailed description of the phenotypes is given in Table SII<sup>1</sup>.

<sup>1</sup><https://doi.org/10.2340/00015555-2304>

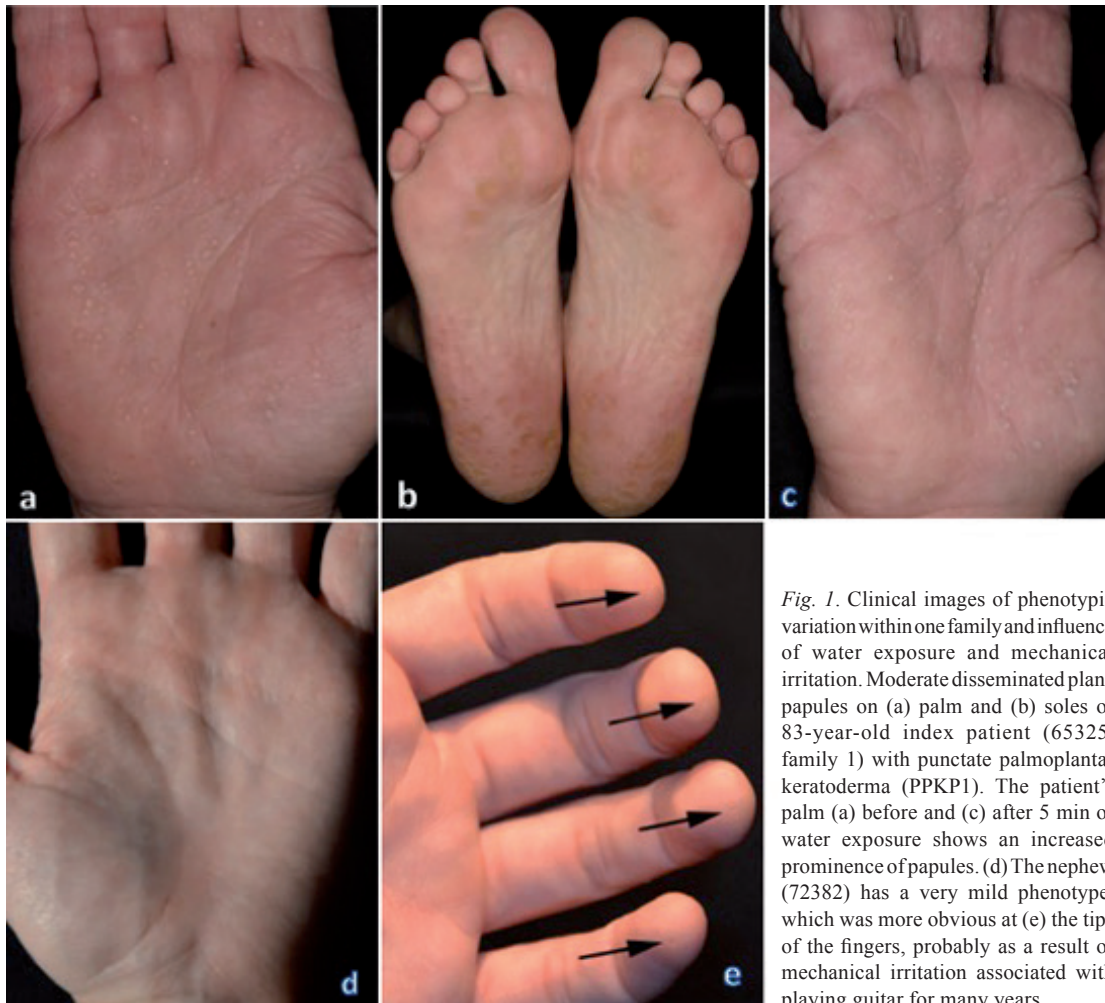

Fig. 1. Clinical images of phenotypic variation within one family and influence of water exposure and mechanical irritation. Moderate disseminated plane papules on (a) palm and (b) soles of 83-year-old index patient (65325, family 1) with punctate palmoplantar keratoderma (PPKP1). The patient's palm (a) before and (c) after 5 min of water exposure shows an increased prominence of papules. (d) The nephew (72382) has a very mild phenotype, which was more obvious at (e) the tips of the fingers, probably as a result of mechanical irritation associated with playing guitar for many years.

The following genotype variants are described in Appendix S1<sup>1</sup>:

- Mutations affecting the start codon
- Missense mutation
- Frameshift mutations
- Nonsense mutations
- Splice site mutations

## DISCUSSION

This study examined 14 families with PPKP1 and identified 8 previously unknown mutations in 9 families, 3 known mutations in 4 families, and a mutation, representing a known SNP in one family. In addition, using molecular genetic analysis, the aim of this study was to establish a genotype–phenotype correlation and examine for inter- and intra-familial phenotypic variability.

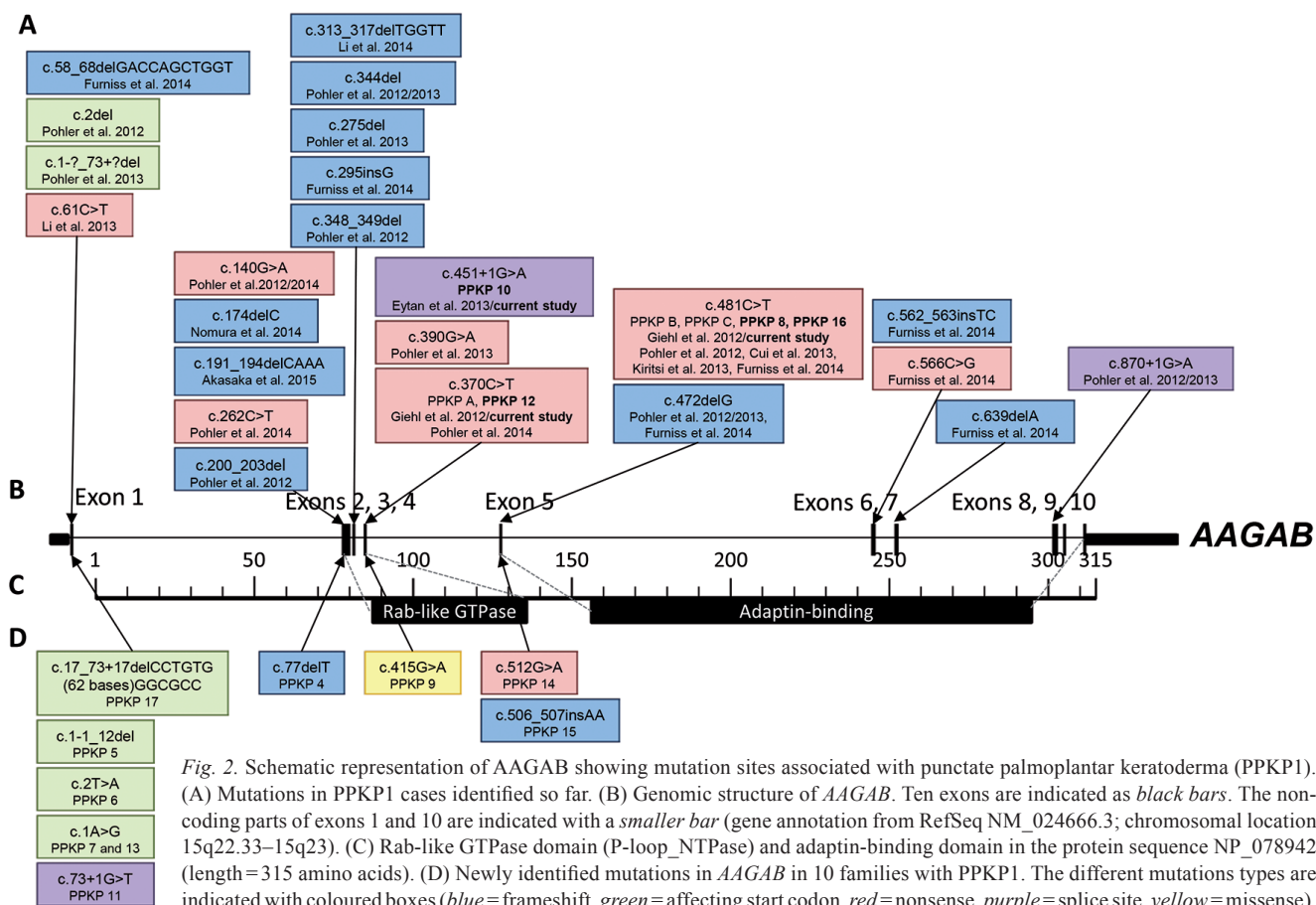
To date, a total of 38 mutations have been reported by several authors in families with PPKP1 Buschke-Fischer-Brauer (2, 12, 19–27), as summarized in Fig. 2. The mutations occurred in a variety of different populations, including individuals of European, Asian, African, Jewish, Mexican and Canadian origin. Among these mutations, 17 were frameshift mutations, 10 nonsense mutations, 6 mutations affecting the start codon, 4

splice site alterations, and 1 missense mutation. Except for exon 3, where only frameshift mutations have been reported, the other mutation types occurred in almost every coding exon of *AAGAB*, with the exception of exons 9 and 10 (Fig. 2). This broad range of mutation types and distribution reflects the high variability of clinical phenotypes among families, but does not explain the intra-familial differences. Although we compared the clinical phenotypes of all patients with different types of mutations, no correlation between the severity of the phenotype and the type or location of the mutation could be identified.

This phenotypic variability within families leads to the assumption that one or more modifier genes interact with *AAGAB* or with the gamma-adaptin and alpha-adaptin subunits involved in clathrin-coated vesicle trafficking, thus influencing the final phenotype.

In our study more women were affected than men (17 women, 9 men) although PPKP1 is inherited in an autosomal dominant manner. One explanation could be that more women are concerned about their skin and therefore more often seek help from a doctor.

The spectrum of the clinical phenotypes between families, within families, and among affected individuals varied extensively. The phenotypes ranged from very mild forms that were recognized only after another





family member with a more severe phenotype was diagnosed, to very severe forms in which the entire sole was affected with such thick hyperkeratosis that the patient required surgery.

We found that the same mutation could lead to different phenotypes (Fig. 1) even in the same family (families 1, 4, 6). An example of clinical variability is shown in family 1 in Fig. 1. In family 4, the index patient had a moderate phenotype, and according to the patient's history, the parents were not affected. For segregation analysis, the genotype of the parents was also examined, which revealed that the father also had the same genotype. A thorough skin examination uncovered only one lesion, which would otherwise have been interpreted as a small wart, but was now interpreted as a minimal affected phenotype. In family 6, the phenotype varied from severe to very mild and clinically almost absent.

The missense mutation in family 6, which is a known SNP with a minor allele frequency of 0.001 (dbSNP; <http://www.ncbi.nlm.nih.gov/SNP/>), is more likely a causal mutation than a rare polymorphism. Due to the low incidence and the possible late onset of the disease, it is very likely that this mutation leads to PPKP1 and that this disease is more common than reported. The segregation analysis also supports this assumption, as all affected members exhibit this mutation. Although this mutation was excluded in unaffected relatives of family 6, it will be necessary to detect this mutation in other independent patients to define its pathogenicity.

Four of the 26 affected individuals (66351 [family 3], 71005 [family 4], 76427 [family 6], 72608 [family 9]), all of whom are from different families, would not have been recognized as PPKP1 without the typical index patients. Mild forms of PPKP1 might often be overlooked or under-reported, and therefore the prevalence of this disease may be underestimated.

The phenotype showing increased prominence of papules upon exposure to water (Fig. 1) has so far been diagnosed as keratosis palmoplantaris maculosa seu papulosa, as in the case of our patient (65325, family 1) and in the literature (28), hereditary chronic translucent papules of the palms and soles (29) or papulotranslucent acrokeratoderma (30, 31). In these cases genetic investigation of the *AAGAB* gene will be necessary to confirm that these are variants of PPKP1.

Also, no correlation was found between the severity of the clinical phenotype and the subjective severity score (Table SII<sup>1</sup>). For example, all 4 affected individuals of family 6 reported relatively high severity scores, although 2 of them had only a mild or moderate phenotype. This demonstrates impressively how even seemingly mild phenotypic expression of PPKP1 can have a profound impact on the patients' quality of life.

In 4 of 26 patients, there was no family history of palmoplantar keratoderma. Because of the phenotypic

variability, it is still possible that these sporadic cases have a familial background. In our cases, it was not possible to elucidate this, as the other family members could not be examined clinically or by molecular genetics.

These observations suggest that environmental factors, such as manual labour, hobbies, walking longer distances, as well as the frequency of mechanical treatment, may influence the phenotypic differences within a family.

The results of the analysis of 26 individuals from 14 families reported in this study, and those of other analyses reported by others, indicate that no clear phenotype–genotype correlation exists in PPKP1. Our findings suggest that there are no correlations with age, but with mechanical factors, and that there is an underestimation of the disease frequency. Differential diagnosis includes calluses due to pressure points, viral warts and porokeratosis punctate palmaris et plantaris and keratoses of toxic or paraneoplastic origin. As some entities of palmoplantar keratoderma are not distinct, they might often be misdiagnosed before the molecular era. The penetrance of PPKP1 seems to be highly variable. Regardless of the genotype, phenotypes vary considerably in PPKP1 and can even mimic other clinical entities of palmoplantar keratoderma.

PPKP1 Buschke-Fischer-Brauer is an example of how genetic characterization can lead to the regrouping of clinical entities and to the definition of new entities.

## ACKNOWLEDGMENTS

The authors would like to thank the patients and their families for their participation in this study. The authors also thank R. Feldmann for technical assistance in mutation analysis, and Diana Lingk for technical assistance with the photographic images. RCB is the recipient of a Heisenberg Professorship from the German Research Council (DFG).

*Electronic database information.* The URLs of databases and predictive software used herein are as follows: Online Mendelian Inheritance in Man (OMIM): <http://www.omim.org>. UCSC Human Genome Browser: <http://genome.cse.ucsc.edu/>. SIFT: <http://sift.jcvi.org/>. PolyPhen-2: <http://genetics.bwh.harvard.edu/pph2/bgi.shtml>. CRYP-SKIP: <http://cryp-skip.img.cas.cz/>. dbSNP: <http://www.ncbi.nlm.nih.gov/SNP/>.

## REFERENCES

- Giehl KA, Eckstein GN, Pasternack SM, Praetzel-Wunder S, Ruzicka T, Lichtner P, et al. Nonsense mutations in AAGAB cause punctate palmoplantar keratoderma type Buschke-Fischer-Brauer. *Am J Hum Genet* 2012; 591: 754–759.
- Eytan O, Sarig O, Israeli S, Mevorah B, Basel-Vanagaite L, Sprecher E. A novel splice-site mutation in the AAGAB gene segregates with hereditary punctate palmoplantar keratoderma and congenital dysplasia of the hip in a large family. *Clin Exp Dermatol* 2014; 39: 182–186.
- Buschke A, Fischer W. Keratoderma maculosa disseminata symmetrica palmaris and plantaris. *Ikonographia Derma-*

- tologica 1910; 51: 183–192.
4. Brauer A. Über eine besondere Form des hereditären Keratoms (keratoderma disseminatum hereditarium palmare et plantare). *Arch Dermatol Syph* 1913; 114: 211–236.
  5. Emmert S, Küster W, Hennies HC, Zutt M, Haenssle H, Kretschmer L, et al. 47 individuals in 14 families with the rare genodermatosis keratosis punctata palmoplantaris Buschke-Fischer-Brauer. *Eur J Dermatol* 2003; 1: 16–20.
  6. Kelsell DP, Stevens HP. The palmoplantar keratoderms: much more than palms and soles. *Mol Med Today* 1999; 5: 107–113.
  7. Braun-Falco M. Hereditary palmoplantar keratoderms. *J Dtsch Dermatol Ges* 2009; 7: 971–984.
  8. Stanimirovic A, Kansky A, Basta-Juzbasic A, Skerlev M, Beck T. Hereditary palmoplantar keratoderma type papulosa, in Croatia. *J Am Acad Dermatol* 1993; 29: 435–437.
  9. Ena P, Cottini F, Cerimele D, Saccabusi S, Retanda G. Association of keratoderma punctata palmaris et plantaris with other morbid conditions (early grayness, carcinoma of the colon). Study of 3 families. *G Ital Dermatol Venereol* 1986; 121: 45–54.
  10. Bennion SD, Patterson JW. Keratosis punctata palmaris et plantaris and adenocarcinoma of the colon. A possible familial association of punctate keratoderma and gastrointestinal malignancy. *J Am Acad Dermatol* 1984; 10: 587–591.
  11. Stevens HP, Kelsell DP, Leigh IM, Ostlere LS, MacDermot K, Rustin MH. Punctate palmoplantar keratoderma and malignancy in a four-generation family. *Br J Dermatol* 1996; 134: 720–726.
  12. Pohler E, Mamai O, Hirst J, Zamiri M, Horn H, Nomura T, et al. Haploinsufficiency for AAGAB causes clinically heterogeneous forms of punctate palmoplantar keratoderma. *Nat Genet* 2012; 14: 1272–1276.
  13. Martinez-Mir A, Zlotogorski A, Londono D, Gordon D, Grunn A, Uribe E, et al. Identification of a locus for type I punctate palmoplantar keratoderma on chromosome 15q22–q24. *J Med Genet* 2003; 40: 872–878.
  14. Zhang, XJ, Li M, Gao TW, He PP, Wei SC, Liu JB, et al. Identification of a locus for punctate palmoplantar keratoderms at chromosome 8q24.13–8q24.21. *J Invest Dermatol* 2004; 122: 1121–1125.
  15. Gao M, Yang S, Li M, Yan KL, Jiang YX, Cui Y, et al. Refined localization of a punctated palmoplantar keratoderma gene to a 5.06 cM region at 15q22.2–15q22.31. *Br J Dermatol* 2005; 152: 874–878.
  16. Bchetnia M, Charfeddine C, Kassas S, Hanchi I, Tounsi-Guettiti H, Rebai A. Clinical, histological and genetic investigation of Buschke-Fischer-Brauer's disease in Tunisian families. *J Dermatol Sci* 2009; 54: 54–56.
  17. El Amri I, Mamai O, Ghariani N, Denguezli M, Sriha B, Adala L, et al. Etude clinique et génétique de la k eratodermie palmopantaire de Buschke-Fischer-Brauer dans une famille tunisienne. *Ann Derm Venerol* 2010; 137: 269–275.
  18. Mamai O, Boussofara L, Adala L, Amara A, Charfeddine BI, Ghariani N, et al. Reduction of palmoplantar keratoderma Buschke-Fischer-Brauer locus to only 0.967 Mb. *J Dermatol Sci* 2012; 68: 116.
  19. Pöhler E, Zamiri M, Harkins CP, Salas-Alanis JC, Perkins W, Smith FJ, et al. Heterozygous mutations in AAGAB cause type 1 punctate palmoplantar keratoderma with evidence for increased growth factor signaling. *J Invest Dermatol* 2013; 133: 2805–2808.
  20. Cui H, Gao M, Wang W, Xiao R, Chen G, Zhang Q, et al. Six novel mutations in AAGAB confirm its pathogenic role in Chinese punctate palmoplantar keratoderma patients. *J Invest Dermatol* 2013; 133: 2631–2634.
  21. Kiritsi D, Chmel N, Arnold AW, Jakob T, Bruckner-Tuderman L, Has C. Novel and recurrent AAGAB mutations: Clinical variability and molecular consequences. *J Invest Dermatol* 2013; 133: 2483–2486.
  22. Li M, Yang L, Shi H, Guo B, Dai X, Yao Z, et al. Loss-of-function mutation in AAGAB gene in Chinese families with punctate palmoplantar keratoderma. *Br J Dermatol* 2013; 169: 168–171.
  23. Li M, Dai X, Cheng R, Yang L, Yao Z, Liu J. A Novel 5-bp Deletion mutation in AAGAB gene in a Chinese family with punctate palmoplantar keratoderma. *Acta Derm Venereol* 2014; 94: 339–340.
  24. Furniss M, Higgins CA, Martinez-Mir A, Horev L, Petukhova L, Stanimirovic A et al. Identification of distinct mutations in AAGAB in families with type 1 punctate palmoplantar keratoderma. *J Invest Dermatol* 2014; 134: 1749–1452.
  25. Pohler E, Huber M, Boonen SE, Zamiri M, Gregersen PA, Sommerlund M, et al. New and recurrent AAGAB mutations in punctate palmoplantar keratoderma. *Br J Dermatol* 2014; 171: 433–436.
  26. Nomura T, Yoneta A, Pohler E, Suzuki S, Osawa R, Mizuno O, et al. Punctate palmoplantar keratoderma type 1: a novel AAGAB mutation and efficacy of etretinate. *Acta Derm Venereol* 2015; 95: 110–111.
  27. Akasaka E, Okawa Y, Nakano H, Takiyoshi N, Rokunohe D, Toyomaki Y, et al. Two Japanese familial cases of punctate palmoplantar keratoderma caused by a novel AAGAB mutation, c.191\_194delCAAA. *J Dermatol Sci* 2015; 78: 156–158.
  28. Schreiber D, Stücker M, Hoffmann K, Bacharach-Buhles M, Altmeyer P. Keratosis palmoplantaris maculosa seu papulosa (Davies-Colley) simulating multiple cornua cutanea. *Hautarzt* 1997; 48: 577–580.
  29. Mervak JE, Lowe L, Cha KB. Chronic translucent papules of the palms and soles. *JAMA Dermatol* 2014; 150: 1001–1002.
  30. Onwukuwe MF, Mihm MC, Toda K. Hereditary papulotranslucent acrokeratoderma: a new variant of familial punctate keratoderma? *Arch Dermatol* 1973; 208: 108–110.
  31. Sracic JK, Krischnan RS, Nunez-Gussman JK, Orengo IF, Hsu S. Hereditary papulotranslucent acrokeratoderma: a case report and literature review. *Dermatol Online J* 2005; 11: 17.