

# Nail Psoriasis: An Updated Review and Expert Opinion on Available Treatments, Including Biologics

Federico BARDAZZI, Michela STARACE, Francesca BRUNI, Michela MAGNANO, Bianca Maria PIRACCINI and Aurora ALESSANDRINI

*Division of Dermatology, Department of Experimental, Diagnostic and Specialty Medicine, University of Bologna, Italy*

**Nail psoriasis affects 50–79% of patients with skin psoriasis and up to 80% of patients with psoriatic arthritis, and can also represent a negative prognostic factor in individuals with plaque psoriasis. Treatments for nail psoriasis are limited, as nails are often difficult to treat with topical therapies alone, and relapse is common. Among different systemic agents, secukinumab, a fully human monoclonal antibody targeting interleukin (IL)-17A, is the only antibody supported by a trial specifically conducted in patients with nail psoriasis (the TRANSFIGURE trial) and has the longest follow-up available to date. In this setting, secukinumab is characterized by the highest efficacy at week 16. This review analysed the different therapeutic options for nail psoriasis, focusing on new treatments that have shown promising results in this field.**

*Key words:* biologic therapy; efficacy; nail psoriasis; systemic therapy; tolerability.

Accepted Dec 6, 2018; E-published Dec 6, 2018

Acta Derm Venereol 2019; 99: 516–523.

*Corr:* Aurora Alessandrini, Department of Experimental, Diagnostic and Specialty Medicine - Division of Dermatology, University of Bologna, Bologna, Italy, Via Massarenti, 1, IT-40138 Bologna, Italy. E-mail: aurora.alessandrini3@unibo.it

Nail psoriasis affects 50–79% of patients with skin psoriasis and up to 80% of patients with psoriatic arthritis (1). The nail matrix or nail bed can be involved by the disease, inducing aesthetic problems and functional damage to patients (2). Clinical manifestations are typical when they involve fingernails, while they can be confusing when the toenails are affected, as they can include subungual hyperkeratosis, which is also a manifestation of onychomycosis. Differential diagnosis is therefore very important in choosing the most appropriate treatment. Diagnosis is based on clinical manifestations, but, in some cases, nail dermoscopy can help the physician to better visualize the alterations not visible to the naked eye. Where diagnosis is uncertain, a biopsy may be mandatory.

The severity of the disease is defined by a validated score, the Nail Psoriasis Severity Index (NAPSI), which is a useful tool for deciding the best treatment and for monitoring the response. The treatment of nail psoriasis is not standardized, ranging from topical therapy to systemic therapy, according to the severity and extension of the disease. Biologic therapies have also been introduced

## SIGNIFICANCE

Nail psoriasis frequently affects patients with skin psoriasis, inducing not only aesthetic problems, but also functional damage. The disease represents a significant burden, impairing patients' quality of life. The treatment of nail psoriasis varies according to disease severity. Topical therapies are used if the nail involvement is mild, but their efficacy is limited and relapses are common. In more serious cases, systemic agents (both traditional and biologic molecules) have shown long-term efficacy. Among biologics, secukinumab is the only agent supported by evidence from a trial specifically conducted in patients with nail psoriasis.

as a treatment option for nail psoriasis, although it is still not clear which is the most effective to treat this particular psoriatic localization.

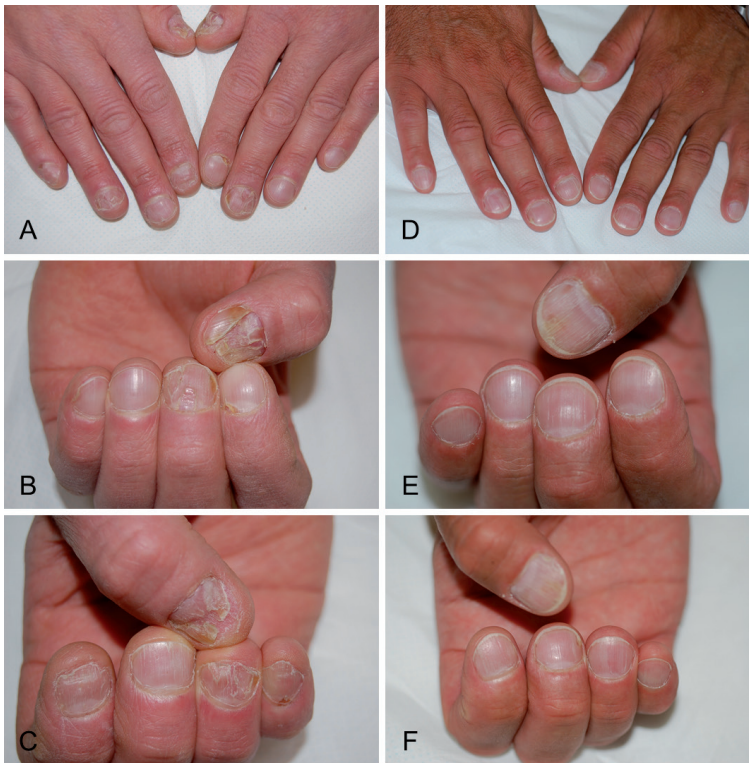## EPIDEMIOLOGY

Psoriasis is a chronic inflammatory disease affecting up to 3% of the general population. The prevalence of nail involvement ranges between 15% and 79% (1, 3–5). Nail psoriasis is less common in children, where the prevalence is 7–13%, while in adults it is more common, even in the absence of skin and joint involvement, reaching a prevalence of 5–10%. Approximately 90% of patients with psoriasis develop nail psoriasis during their life, and it does not appear to be related to the sex or age of the patient (6).

## CLINICAL MANIFESTATIONS

Clinical manifestations of nail psoriasis depend on the affected site of the nail, which can be the nail matrix, the nail bed, the proximal nail fold or the hyponychium (7). All nails or only a few fingernails or toenails can be involved (**Fig. 1A–C**).

When the disease affects the nail matrix, the most severe nail changes are observed, and include pitting, lunulae red spots and nail plate crumbling. Pitting is a very characteristic manifestation of nail psoriasis, and is diagnosed by the presence of small depressions on the nail plate surface. The pathogenetic mechanism of pitting is due to a focal defect of keratinization of the proximal matrix, with persistence of nucleated and incompletely keratinized (parakeratotic) cells within the upper layers



**Fig. 1. Clinical manifestation of nail psoriasis, with crumbling and onycholysis (A–C) before and (D–F) after 24 weeks of treatment with secukinumab.**

in the dorsal nail plate, which are easily detachable, leaving the pits on the surface of the nail plate (8). Psoriatic pits are usually large, and deep, with irregular shape and distribution, and are typically found on the fingernails. While pitting can also be observed in other diseases, such as alopecia areata and eczema, in these conditions it has different characteristics. Red spots on the lunulae (mottled lunulae) are considered to be non-specific manifestations of nail matrix psoriasis, as they can also be present in other diseases, such as nail lichen planus and eczema. When nail matrix involvement is severe, the nail plate can become fragile and deformed, which can lead to crumbling.

Alterations of the nail bed due to psoriasis decrease nail plate adhesion and cause onycholysis, subungual hyperkeratosis, oil-drop or salmon spots and splinter haemorrhages, all of which are considered non-specific manifestations of the disease. In nail bed psoriasis, an erythematous border surrounds the areas of onycholysis, which is very typical and diagnostic (8). Another sign of nail bed psoriasis, more frequently observed at the toenail, is subungual hyperkeratosis, defined as an accumulation of scales under the distal portion of the nail plate, with nail thickening and uplifting. The “oil drop sign” or salmon patches appear as an irregular area of yellow-orange discoloration, which is easily visible through the transparent nail plate (9) and is very typical, while the presence of splinter haemorrhages, appearing as longitudinal linear red-brown areas of haemorrhage,

almost always seen in fingernails, is not specific to psoriasis.

## DIAGNOSIS

The diagnosis of nail psoriasis is usually based on clinical manifestations, but many features may confuse an inexperienced physician. For example, nail discoloration or subungual hyperkeratosis observed in nail psoriasis may also be present in onychomycosis. In these cases, dermoscopy can be very helpful for diagnosis, as the nail can be assessed in its entirety under high magnification.

Nail psoriasis may present with an extremely wide spectrum of symptoms, which vary in severity and type. Dermoscopy can be helpful for the diagnosis of psoriasis when the clinical features are not typical. Dry dermoscopy is recommended to visualize the alteration of the surface nail plate, which are more typical when the nail matrix is involved, while dermoscopy with ultrasound gel is recommended in cases of suspected nail bed psoriasis. A magnification power of 40- to 70-times is utilized to better visualize nail plate and nail bed abnormalities. High magnification permits the

detection of sub-clinical signs that can be very helpful for a definitive diagnosis of nail psoriasis in doubtful cases.

On the nail plate, a dry dermoscopy enhanced visualization of superficial nail plate changes (pitting) shows pits that are large, deep, irregular in size and shape and irregularly distributed, easily distinguishable from those of alopecia areata, which are large, regular in size and shape and regularly distributed. Diffuse scales may be present, especially in the proximal part of the nail, resulting from the proximal matrix involvement.

In patients with nail psoriasis onycholysis, dermoscopy with ultrasound gel underline the erythematous border surrounding the distal edge of the detachment, which appears as a slightly dented margin surrounded by a yellow-orange band, while in onychomycosis it shows a jagged proximal edge with spikes of onycholysis and longitudinal striae (10).

Splinter haemorrhages, typically appearing as thin, longitudinal lines on the nail bed can also be magnified. When looking at the hyponychium, irregularly distributed, dilated and tortuous capillaries are observed in patients with splinter haemorrhages, which correlate with disease severity and response to treatment. Dermoscopy of the hyponychium is very helpful to confirm the diagnosis of psoriasis in patients with simple onycholysis or mild nail bed hyperkeratosis. Splinter haemorrhages are best visualized at 40-times magnification, but can also be observed with a handheld dermatoscope, where they look like red dots (11). Capillary loops can also look

like red dots with a hand dermatoscope (12), and may also be seen in the proximal fold when it is inflamed. At the toenails, nail psoriasis is characterized by subungual hyperkeratosis, which has to be distinguished from onychomycosis. Thus mycology is essential in most cases. It is not uncommon that onychomycosis and psoriasis coexist in the same nail (13).

Dermoscopy of the hyponychium may be a useful supportive tool for differentiating early psoriatic arthritis from early rheumatoid arthritis. Differential diagnosis of these 2 diseases may be quite difficult, as both may present with symmetrical articular involvement. In patients with psoriatic arthritis, dermoscopy shows diffusely distributed, red, dotted vessels. In contrast, in patients with rheumatoid arthritis, it is possible to observe 3 vascular patterns: irregular, blurry, purple vessels or avascular appearance or sparse, dotted, purple vessels (14).

Nail biopsy may be necessary in selected cases. In particular, a matrix or nail bed biopsy is chosen based on the clinical manifestation of nail psoriasis, and Periodic Acid-Schiff staining for differential diagnosis with onychomycosis is always recommended (15).

Recently, newer techniques, such as ultrasonography, have been proposed for the diagnosis of nail psoriasis, representing an interesting field of research. Ultrasonography of psoriatic nails shows hyperechoic parts or loss of definition of the nail plates, which can involve the whole nail or only the ventral part. The nail bed is thickened and can show, with the use of power Doppler techniques, an increased blood flow (16). Optical coherence tomography is an instrument that provides images of tissue pathology *in situ*, and, used in nail psoriasis, shows a grossly dishomogeneous ventral nail plate irregularly fused with the underlying epidermis (17). Confocal laser scanning microscopy can visualize cell structures of the skin up to a depth of 300  $\mu\text{m}$  *in vivo* in a non-invasive way (18).

## SEVERITY SCORES

Due to the variability of its clinical manifestations, scoring nail psoriasis has always represented a true challenge for clinicians. In fact, none of the current scores have ever been completely validated, as each presents several limitations and they are often difficult to use in daily practice. The first available score, the Psoriasis Nail Severity Score (PNSS), was proposed by a group of rheumatologists in 1994, and only partially evaluates the psoriatic nail features (19). Two other scores, the Nail Area Score (NAS) (20) and a scoring system proposed by Cannavò and colleagues (21) were introduced a few years later, differing from the first score for the introduction of a nail alteration severity grading system. However, the most-used score to determine the severity of nail psoriasis is the NAPSI, which considers the most characteristic lesions of nail psoriasis and divides them into 2 cate-

gories; some belonging to the nail bed (such as splinter haemorrhages, oil drop discolorations, onycholysis and nail bed hyperkeratosis), others belonging to the nail matrix (such as pitting, leukonychia, red spots in the lunulae and nail plate crumbling). When using the NAPSI, clinicians should score the presence or the absence of each lesion belonging to one of the aforementioned categories. The final score is the sum of the scores for each nail (0–80 for 10 fingernails, 0–160 if toenails are included) (22).

The classic NAPSI score was very complicated and did not consider the severity of each lesion. To address this issue, the target NAPSI, which considered only the most affected nail, and the modified NAPSI, which graded the entity of each nail alterations, were also created (23). In 2004, Baran created a nail psoriasis severity index score, which considers 5 psoriatic nail features (pitting, Beau's lines, subungual hyperkeratosis, onycholysis and splinter haemorrhages) and their severity (24). More recently, 2 other scores have been proposed, the Nail Assessment in Psoriasis and Psoriatic Arthritis (NAPPA) (25), which uses 2 questionnaires focused on the patient's quality of life and their expectations about therapy, and the Nijmegen-Nail psoriasis Activity Index tool (N-NAIL), which considers 5 nail features (onycholysis, Beau's lines, pitting, crumbling and subungual hyperkeratosis) and scores them from absent to severe on a 4-point scale (0–3) (26).

Although several scoring systems have so far been proposed for nail psoriasis, there is a lack of consensus on the most appropriate of these measures, due to their lack of reproducibility and their difference in selection and type of scoring of included features (27).

## AVAILABLE TREATMENTS FOR NAIL PSORIASIS

Treatments for nail psoriasis are still limited. Nails are often difficult to treat with topical therapies, and relapses are common. Furthermore, systemic agents take some time to reach the particular sites, delaying response, and conventional systemic therapy, including, cyclosporine, methotrexate, and retinoids, can cause organ toxicities in the long term (6).

The management of nail psoriasis should be based on both clinical involvement and the patient's quality of life, which is often dramatically affected by the disease. The presence of psoriatic arthritis should also be considered in the choice of the best therapeutic strategy. Current therapies for the treatment of nail psoriasis are shown in **Table I**.

### Topical therapies

If the nail involvement is mild, quality of life is not seriously compromised, and psoriatic arthritis is absent, nail psoriasis should be managed only with topical therapies. Available topical treatments include steroids, the vitamin



**Table I. Current therapies for treatment of nail psoriasis**

<i>Topical therapies</i>	
Corticosteroids	
Vitamin D3 analogues	
Calcipotriol	
Tacalcitol	
Calcitriol	
Tazarotene	
Calcineurin inhibitors	
5-fluorouracil	
Apremilast nail lacquer	
<i>Phototherapy</i>	
Narrow-band UVB	
UVA	
<i>Systemic therapies</i>	
Acitretin	
Cyclosporine	
Methotrexate	
TNF- $\alpha$ inhibitors	
Infliximab	
Etanercept	
Adalimumab	
Certolizumab	
Golimumab	
Anti-interleukin agents	
Ustekinumab	
Secukinumab	
Ixekizumab	
T-cell modulators	
Apremilast	
Small molecule inhibitors	
Tofacitinib	

D3 analogues calcipotriol, tacalcitol and calcitriol, used in monotherapy or in combination with corticosteroids, tazarotene, topical calcineurin inhibitors, 5-fluorouracil and, more recently, apremilast nail lacquer (6).

Topical steroids are probably the most-used topical therapies, both in plaque and nail psoriasis and, in nail psoriasis, they seem to be more effective in treating nail matrix disease than nail bed disease. They can be applied in several different formulations, such as ointments, creams, lotions, emulsions, and even nail lacquers. In all of these, the prolonged use of topical steroids has caused telangiectasia of the surrounding skin and atrophy. Furthermore, if topical steroids are used over several years, studies have documented a possible tapering of the treated digit, which can be caused by atrophy of the underlying phalanx, and is commonly known as “disappearing digit” (28, 29). Therefore, the use of topical steroids should be limited or used in combination with other topical therapies.

Vitamin D derivatives regulate cell proliferation and differentiation and are widely used in both nail and plaque psoriasis. Unlike the topical steroids, they have demonstrated increased efficacy on nail bed lesions, such as subungual hyperkeratosis, onycholysis, and discoloration. Calcipotriol is the most common vitamin D derivative used for the treatment of nail psoriasis, alone or in combination with other topical treatments. A study of the combination of calcipotriol and betamethasone dipropionate in an ointment formulation did not demonstrate better efficacy than calcipotriol alone in a comparative study conducted in patients with mild nail

psoriasis (30). However, a recent case report has shown the successful use of a calcipotriol/betamethasone dipropionate gel after 6 weeks of treatment in a patient with severe nail psoriasis (31).

Although several studies have been conducted on the use of tazarotene and topical calcineurin inhibitors in patients with nail psoriasis, their use is limited by their potential side-effects. Topical tazarotene can often cause erythema, irritation, and desquamation, while calcineurin inhibitors have been associated with acute paronychia. Topical formulations of anthralin and 5-fluorouracil are also now used only rarely for nail psoriasis, due to frequent adverse effects (pigmentation of the nail bed and inflammation, infection, discoloration or onycholysis, respectively) and their doubtful efficacy (4).

Intralesional corticosteroids have a long history in the treatment of nail psoriasis, and they can be administered by needle injection or high-pressure jet from a tool such as the “Port-O-Jet” or “Med-Jet MBX”. Needle injection of triamcinolone acetonide (5–10 mg/ml) monthly or every 2 months is still the most common method, and it seems to have good efficacy on the nail matrix lesions. However, side-effects, such as short-term paraesthesia, long-lasting focal pain, haematomas and nail fold atrophy, limit its use (4).

#### *Systemic agents*

Systemic therapies are not recommended for the treatment of isolated nail psoriasis, unless nail involvement causes functional impairment, reduced quality of life or when the pathology is resistant to topical therapy (32). In addition, systemic treatments are considered when nail psoriasis is concomitant to severe skin disease (32). Physicians have multiple choices that encompass both traditional systemic (acitretin, cyclosporine, methotrexate and phototherapy) and biotechnological therapies (from the most common tumour necrosis factor (TNF)- $\alpha$  inhibitors and anti-IL agents to the new T-cell modulators and small molecule inhibitors) (32). Choosing the most appropriate therapy is not easy due to the limited number of studies that have focused on the response of these therapies in patients with nail psoriasis. However, a retrospective study conducted by Sánchez-Regaña and colleagues has demonstrated that all traditional and biologic systemic treatments significantly reduce NAPSII scores (32).

*Acitretin.* Low doses of acitretin (0.2–0.3 mg/kg/day) have been reported to induce a 40% reduction of the NAPSII in 24 weeks. Moreover, acitretin seems to be particularly effective on subungual hyperkeratosis (33). However, it has failed to achieve significant improvements in nail psoriasis (34).

*Cyclosporine.* Among traditional treatments, cyclosporine appears to be the most effective, mainly for its long-term improvements on both the nail matrix and bed (32). It is important to prescribe it for no longer than 6 months.

Furthermore, a randomized trial demonstrated the superiority of cyclosporine over retinoids (35), while other studies have demonstrated that cyclosporine is as effective as biologic therapies (36), particularly adalimumab. *Methotrexate*. Methotrexate has demonstrated similar efficacy to acitretin. However, data on its use in nail psoriasis are lacking (37). Despite this, many physicians consider it to be beneficial for both skin and nail psoriasis (32).

*Phototherapy*. Phototherapies for the treatment of nail psoriasis include ultraviolet B (UVB) and psoralen and ultraviolet A (UVA), as well as their combination with retinoids. Studies have shown that phototherapy is effective for the treatment of nail psoriasis, but there is no consensus among the experts. It is important to note that narrow-band UVB (32) and UVA do not reach the proximal matrix itself through the nail plate, resulting in a variable efficacy on nail psoriasis.

*TNF- $\alpha$  inhibitors*. Introduced in 2007, TNF- $\alpha$  inhibitors were the first biotechnological therapies used for the treatment of psoriasis (38). The group includes infliximab, etanercept, adalimumab, certolizumab and golimumab (39). Infliximab is a chimeric monoclonal antibody against TNF- $\alpha$  (39). Its efficacy for the treatment of plaque psoriasis was demonstrated in the EXPRESS randomized controlled trial, with significant improvement in disease observed at weeks 10 and 24 vs. placebo (40). Subsequently, the PSUNRISE randomized controlled trial (RCT) demonstrated the value of infliximab in patients with moderate-to-severe psoriasis who had inadequately responded to etanercept treatment (41). Etanercept is a dimeric fusion protein that binds soluble TNF- $\alpha$  and has been shown to improve psoriasis after 12 and 24 weeks of therapy (42, 43). The National Psoriasis Foundation recommends etanercept in patients with isolated nail psoriasis, as well as in patients who have nail and skin disease and those who have nail, skin and joint disease (44). Adalimumab is a human monoclonal antibody with high affinity for TNF- $\alpha$  (39), and its effectiveness for the treatment of nail psoriasis has been investigated in RCTs (45, 46) and observational studies (47, 48). These studies all demonstrated an improvement in NAPSI, and as such, the National Psoriasis Foundation has recommended the use of adalimumab in patients with nail disease alone, skin and nail disease or a combination of skin, nail and joint disease (44). Adalimumab can be used alone or in combination with cyclosporine, as well as in patients in whom methotrexate is ineffective or who have failed to respond to other TNF- $\alpha$  inhibitors (49). Furthermore, compared with other recommended therapies for nail psoriasis, patients receiving adalimumab reported having higher enthusiasm for the treatment, which has been shown to be associated with reduced disability and improved quality of life (39). In a randomized, phase 3 trial vs. placebo, significant improvements were seen at 26 weeks in the 75% improvement in total-fingernail

modified NAPSI (NAPSI75) response rate, and in other efficacy endpoints (46).

Other effective TNF- $\alpha$  inhibitors available for the treatment of nail psoriasis are certolizumab, a PEGylated Fab portion of a humanized monoclonal antibody against TNF- $\alpha$  (50), and golimumab, a monoclonal antibody engineered in a transgenic mice model (51). However, in the studies for both of these agents, patients also received treatment with other systemic agents (such as methotrexate, sulfasalazine, leflunomide, or oral corticosteroids), which may be confounding factors for the response observed with these treatments.

Comparative studies among TNF- $\alpha$  inhibitors have failed to demonstrate clinically important differences in NAPSI reduction (52).

*Anti-interleukin drugs*. Immunological research has highlighted the central role of IL-17 and IL-23 in the pathogenic pathway of psoriasis (6). Introduced into clinical dermatological practice after the introduction of the TNF- $\alpha$  inhibitors, the anti-IL drugs available for the treatment of nail psoriasis are ustekinumab (IL-12 and IL-23 inhibitor), secukinumab and ixekizumab (both IL-17 inhibitors) (39).

Ustekinumab is a human monoclonal antibody that targets the p40 subunit of both IL-12 and IL-23, and which has been shown to be effective in the treatment of nail psoriasis (53). Ustekinumab was evaluated in a retrospective study that aimed to determine the most effective biologic therapy for the treatment of nail psoriasis. However, the authors did not find any statistically significant difference between ustekinumab and the other drugs investigated (infliximab, adalimumab, etanercept) (54).

Ixekizumab is a humanized monoclonal antibody against IL-17A. Although ixekizumab has demonstrated promising results in the treatment of nail psoriasis, this evidence comes only from *post-hoc* analyses of clinical trials conducted in patients with plaque psoriasis. For instance, in a *post-hoc* analysis of a phase 2, randomized, placebo-controlled trial (55), significant improvements in NAPSI were observed after 20 weeks of treatment in patients who received ixekizumab compared with those who received placebo. These findings were mirrored in another *post-hoc* analysis of the phase 3, multicentre, double-blind, placebo- and active-controlled UNCOVER-3 trial. In the trial, ixekizumab was associated with a significantly greater improvement in NAPSI compared with placebo and etanercept after 12 weeks of treatment (56).

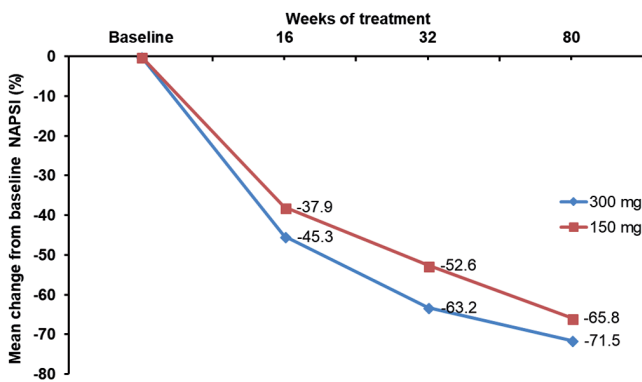
Secukinumab is a fully human monoclonal antibody against IL-17A and is one of the latest biological therapies introduced for the treatment of both skin and nail psoriasis (57). At present, it is the only fully human monoclonal antibody against IL-17A available in this setting. The second panel of Fig. 1 (D–F) shows images after treatment of nail psoriasis with secukinumab, illustrating our clinical experience with this human monoclonal anti-

body against IL-17A. As can be seen, significant improvement has been achieved after 24 weeks of secukinumab treatment. The efficacy of secukinumab was investigated in the randomized, double-blind, placebo-controlled, parallel-group, phase 3 TRANSFIGURE study, which included patients with moderate-to-severe psoriasis with nail involvement. Of note, this is the only trial of an anti-IL-17A agent conducted to date specifically in patients with nail psoriasis; the carrying out of well-designed trials in this population has been proposed as a major goal of research in the field (27). The primary outcome of TRANSFIGURE was to determine the superiority of secukinumab 150 mg and 300 mg vs. placebo in the change from baseline in NAPSI at 16 weeks, while secondary outcomes included the Psoriasis Area Severity Index (PASI) 75 and 90 response rates of both dosages. The results of TRANSFIGURE have been progressively reported at international meetings. To date, all outcomes of the TRANSFIGURE study have been achieved, with patients receiving secukinumab 150 or 300 mg having significantly greater reductions in NAPSI at week 16 compared with placebo (57) (Fig. 2)<sup>1</sup>. Moreover, high levels of skin clearance were seen with secukinumab treatment by week 16. Among all prospective, placebo-controlled trials evaluating treatments for nail psoriasis, the outcomes observed with secukinumab in the TRANSFIGURE study show the highest week 16 efficacy reported to date (57). No relevant safety signals have been reported. The TRANSFIGURE trial also has had the longest follow-up currently available among all studies of anti-IL17A agents in the setting of nail psoriasis. At the 32-week analysis of this trial, responses further improved, with a NAPSI change of -63.2% for the 300 mg dose and -52.6% for the 150 mg dose (Fig. 2)<sup>2</sup>. PASI 90 responses were achieved in 72.1% and 61.4% of subjects, respectively (Fig. 3A, while PASI 100 responses were

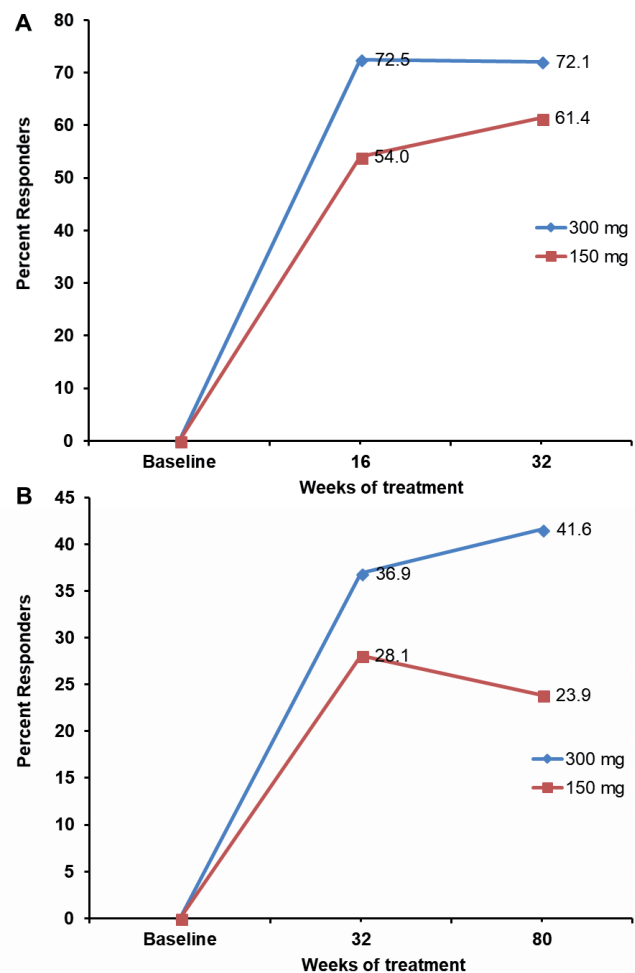
achieved in 36.9% and 28.1% of patients, respectively, for secukinumab 300 mg and 150 mg (Fig. 3B).

Further follow-up shows continued improvement from baseline NAPSI at week 80 (Fig. 2), together with week 80 PASI 100 responses in 41.6% and 23.9% of patients for secukinumab 300 mg and 150 mg, respectively (Fig. 3B)<sup>3</sup>. Moreover, reductions in total mean NAPPA-QOL (quality of life) and NAPPA-PBI (Patient Benefit Index) was observed, corresponding to disease improvement associated with secukinumab.

The benefit of secukinumab treatment has now been shown to be sustained through 2.5 years of follow-up, with a large mean improvement in NAPSI from baseline with secukinumab 300 and 150 mg, accompanied with



**Fig. 2. Change in Nail Psoriasis Severity Index (NAPSI) score during the first 80 weeks of treatment with secukinumab 150 mg or secukinumab 300 mg in the TRANSFIGURE trial.**



**Fig. 3. Psoriasis Area Severity Index (PASI) (A) 90 and (B) 100 response rates up to Week 80 of treatment with secukinumab 150 or secukinumab 300 mg in the TRANSFIGURE trial.**

<sup>1</sup>Reich K, Sullivan J, Arenberger P, Mrowietz U, Jazayeri S, Regnault P, et al. Secukinumab is effective in subjects with moderate to severe plaque psoriasis with significant nail involvement: 16 week results from the TRANSFIGURE study. Poster presented at the 23<sup>rd</sup> World Congress of Dermatology, Vancouver, Canada June 8–13, 2015.

<sup>2</sup>Reich K, Sullivan J, Arenberger P, Mrowietz U, Jazayeri S, Augustin M, et al. Secukinumab shows significant efficacy in nail psoriasis: Week 32 results from the TRANSFIGURE study. *Ann Rheum Dis* 2016; 75: 603. Poster presented at the 25<sup>th</sup> European Academy of Dermatology and Venerology Congress, Vienna, Austria September 28–October 2, 2016.

<sup>3</sup>Reich K, Arenberger P, Mrowietz U, Jazayeri S, Augustin M, Parmex A, et al. Secukinumab shows high and sustained efficacy in nail psoriasis: Week 80 results from the Transfigure study. *J Am Acad Dermatol* 2017; 76: Poster presented at the 8<sup>th</sup> international Psoriasis From Gene to Clinic Congress, London, UK November 30–December 2, 2017 (PO20).



a sustained reduction both in total mean NAPPA-QOL and NAPPA-PBI global score<sup>4</sup>.

**T-cell modulators.** This class of drugs includes inhibitors of T-cell co-stimulatory molecules and phosphodiesterase (PDE) 4 inhibitors (39). Among them, promising results have been seen only with apremilast, a PDE-4 inhibitor that increases levels of cyclic adenosine monophosphate (cAMP) and reduces the levels of pro-inflammatory cytokines (58). Based on the results of this study, the National Psoriasis Foundation recommends its use for the treatment of nail psoriasis, though in a lower ranking than for some other agents (44).

**Small molecule inhibitors.** Tofacitinib is a Janus-kinase inhibitor. Two 52-week, randomized, controlled phase 3 studies in patients with moderate-to-severe plaque psoriasis showed that tofacitinib treatment resulted in improvements in nail psoriasis vs. placebo at week 16, as measured by NAPS150, NAPS175, or NAPS1100; improvements were maintained over 52 weeks (59).

## CONCLUSION

Many therapeutic options are now available to the physician treating nail psoriasis. In clinical studies, cyclosporine, TNF- $\alpha$  inhibitors and anti-IL drugs have demonstrated comparable overall efficacy and long-term results in this indication. However, secukinumab, an anti-IL17A fully human monoclonal antibody, has shown high efficacy to date up to Week 80 when considering all prospective, double-blind trials. Moreover, this agent not only has the longest follow-up to date, but also is the only agent in its class supported by evidence derived from a trial specifically conducted in patients with nail psoriasis. Our clinical experience with the use of secukinumab in our patients with nail psoriasis supports the beneficial effects seen in the TRANSFIGURE study.

Nail psoriasis is often not recognized and is undertreated and difficult to score, which complicates the performing of good quality studies with large patient cohorts. Moreover, with the introduction of new molecules, other comparative studies among biologic therapies or systemic and biologic agents are now needed to determine the best approach for the management of this often challenging and distressing clinical entity.

## ACKNOWLEDGEMENTS

The authors thank Simone Boniface and Georgii Filatov of Springer Healthcare Communication, and Luca Giacomelli, an independent medical writer, for English language editing and formatting of the manuscript for submission.

<sup>4</sup>Reich K, Arenberger P, Mrowietz U, Jazayeri S, Augustin M, Parneix A, et al. Secukinumab shows high and sustained efficacy in nail psoriasis: 2.5-year results from the TRANSFIGURE study. Oral presentation at the 8th 2017 international Psoriasis From Gene to Clinic Congress, London, United Kingdom November 30–December 2, 2017 (PO21).

The medical writing assistance for this manuscript was funded by Novartis.

*The authors have no conflicts of interest to declare.*

## REFERENCES

- Bardazzi F, Lambertini M, Chessa MA, Magnano M, Patrizi A, Piraccini BM. Nail involvement as a negative prognostic factor in biological therapy for psoriasis: a retrospective study. *J Eur Acad Dermatol Venereol* 2017; 31: 843–846.
- Baran R. The burden of nail psoriasis: an introduction. *Dermatology* 2010; 221 Suppl 1: 1–5.
- Reich K. Approach to managing patients with nail psoriasis. *J Eur Acad Dermatol Venereol* 2009; 23 Suppl 1: 15–21.
- Pasch MC. Nail psoriasis: a review of treatment options. *Drugs* 2016; 76: 675–705.
- de Jong EM, Seegers BA, Gulinck MK, Boezeman JB, van de Kerkhof PC. Psoriasis of the nails associated with disability in a large number of patients: results of a recent interview with 1,728 patients. *Dermatology* 1996; 193: 300–303.
- Ventura A, Mazzeo M, Gaziano R, Galluzzo M, Bianchi L, Campione E. New insight into the pathogenesis of nail psoriasis and overview of treatment strategies. *Drug Des Devel Ther* 2017; 11: 2527–2535.
- de Berker D. Nail anatomy. *Clin Dermatol* 2013; 31: 509–515.
- Jiaravuthisan MM, Sasseville D, Vender RB, Murphy F, Muhn CY. Psoriasis of the nail: anatomy, pathology, clinical presentation, and a review of the literature on therapy. *J Am Acad Dermatol* 2007; 57: 1–27.
- Edwards F, de Berker D. Nail psoriasis: clinical presentation and best practice recommendations. *Drugs* 2009; 69: 2351–2361.
- Piraccini BM, Balestri R, Starace M, Rech G. Nail digital dermoscopy (onychoscopy) in the diagnosis of onychomycosis. *J Eur Acad Dermatol Venereol* 2013; 27: 509–513.
- Iorizzo M, Dahdah M, Vincenzi C, Tosti A. Videodermoscopy of the hyponychium in nail bed psoriasis. *J Am Acad Dermatol* 2008; 58: 714–715.
- Lencastre A, Lamas A, Sa D, Tosti A. Onychoscopy. *Clin Dermatol* 2013; 31: 587–593.
- Klaassen KM, Dulak MG, van de Kerkhof PC, Pasch MC. The prevalence of onychomycosis in psoriatic patients: a systematic review. *J Eur Acad Dermatol Venereol* 2014; 28: 533–541.
- Errichetti E, Zabotti A, Stinco G, Quartuccio L, Sacco S, De Marchi G, et al. Dermoscopy of nail fold and elbow in the differential diagnosis of early psoriatic arthritis sine psoriasis and early rheumatoid arthritis. *J Dermatol* 2016; 43: 1217–1220.
- Grover C, Reddy BS, Uma Chaturvedi K. Diagnosis of nail psoriasis: importance of biopsy and histopathology. *Br J Dermatol* 2005; 153: 1153–1158.
- Gutierrez M, Wortsman X, Filippucci E, De Angelis R, Filosa G, Grassi W. High-frequency sonography in the evaluation of psoriasis: nail and skin involvement. *J Ultrasound Med* 2009; 28: 1569–1574.
- Aydin SZ, Ash Z, Del Galdo F, Marzo-Ortega H, Wakefield RJ, Emery P, et al. Optical coherence tomography: a new tool to assess nail disease in psoriasis? *Dermatology* 2011; 222: 311–313.
- Sattler E, Kaestle R, Rothmund G, Welzel J. Confocal laser scanning microscopy, optical coherence tomography and transonychia water loss for in vivo investigation of nails. *Br J Dermatol* 2012; 166: 740–746.
- Jones SM, Armas JB, Cohen MG, Lovell CR, Evison G, McHugh NJ. Psoriatic arthritis: outcome of disease subsets and relationship of joint disease to nail and skin disease. *Br J Rheumatol* 1994; 33: 834–839.
- de Jong EM, Menke HE, van Praag MC, van De Kerkhof PC. Dystrophic psoriatic fingernails treated with 1% 5-fluorouracil in a nail penetration-enhancing vehicle: a double-blind study. *Dermatology* 1999; 199: 313–318.
- Cannavò SP, Guarneri F, Vaccaro M, Borgia F, Guarneri B. Treatment of psoriatic nails with topical cyclosporin: a prospective, randomized placebo-controlled study. *Dermatology*

- 2003; 206: 153–156.
22. Rich P, Scher RK. Nail Psoriasis Severity Index: a useful tool for evaluation of nail psoriasis. *J Am Acad Dermatol* 2003; 49: 206–212.
  23. Parrish CA, Sobera JO, Elewski BE. Modification of the Nail Psoriasis Severity Index. *J Am Acad Dermatol* 2005; 53: 745–746; author reply 746–747.
  24. Baran RL. A nail psoriasis severity index. *Br J Dermatol* 2004; 150: 568–569.
  25. Augustin M, Blome C, Costanzo A, Dauden E, Ferrandiz C, Girolomoni G, et al. Nail Assessment in Psoriasis and Psoriatic Arthritis (NAPPA): development and validation of a tool for assessment of nail psoriasis outcomes. *Br J Dermatol* 2014; 170: 591–598.
  26. Klaassen KM, van de Kerkhof PC, Bastiaens MT, Plusjé LG, Baran RL, Pasch MC. Scoring nail psoriasis. *J Am Acad Dermatol* 2014; 70: 1061–1066.
  27. Kyriakou A, Patsatsi A, Sotiriadis D. Biologic agents in nail psoriasis: efficacy data and considerations. *Expert Opin Biol Ther* 2013; 13: 1707–1714.
  28. Requena L, Zamora E, Martin L. Acroatrophy secondary to long-standing applications of topical steroids. *Arch Dermatol* 1990; 126: 1013–1014.
  29. Deffer TA, Goette DK. Distal phalangeal atrophy secondary to topical steroid therapy. *Arch Dermatol* 1987; 123: 571–572.
  30. Tzung TY, Chen CY, Yang CY, Lo PY, Chen YH. Calcipotriol used as monotherapy or combination therapy with betamethasone dipropionate in the treatment of nail psoriasis. *Acta Derm Venereol* 2008; 88: 279–280.
  31. Tan ES, Oon HH. Effective treatment of severe nail psoriasis using topical calcipotriol with betamethasone dipropionate gel. *Indian J Dermatol Venereol Leprol* 2016; 82: 345–347.
  32. Sánchez-Regaña M, Sola-Ortigosa J, Alsina-Gibert M, Vidal-Fernández M, Umbert-Millet P. Nail psoriasis: a retrospective study on the effectiveness of systemic treatments (classical and biological therapy). *J Eur Acad Dermatol Venereol* 2011; 25: 579–586.
  33. Tosti A, Ricotti C, Romanelli P, Cameli N, Piraccini BM. Evaluation of the efficacy of acitretin therapy for nail psoriasis. *Arch Dermatol* 2009; 145: 269–271.
  34. Mukai MM, Poffo IF, Werner B, Brenner FM, Lima Filho JH. NAPS I utilization as an evaluation method of nail psoriasis in patients using acitretin. *An Bras Dermatol* 2012; 87: 256–262.
  35. Mahrle G, Schulze HJ, Färber L, Weidinger G, Steigleder GK. Low-dose short-term cyclosporine versus etretinate in psoriasis: improvement of skin, nail, and joint involvement. *J Am Acad Dermatol* 1995; 32: 78–88.
  36. Karanikolas GN, Koukli EM, Katsalira A, Arida A, Petrou D, Komninou E, et al. Adalimumab or cyclosporine as monotherapy and in combination in severe psoriatic arthritis: results from a prospective 12-month nonrandomized unblinded clinical trial. *J Rheumatol* 2011; 38: 2466–2474.
  37. Lee JY. Severe 20-nail psoriasis successfully treated by low dose methotrexate. *Dermatol Online J* 2009; 15: 8.
  38. Pathirana D, Ormerod AD, Saiag P, Smith C, Spuls PI, Nast A, et al. European S3-guidelines on the systemic treatment of psoriasis vulgaris. *J Eur Acad Dermatol Venereol* 2009; 23 Suppl 2: 1–70.
  39. Elyoussfi S, Thomas BJ, Ciurtin C. Tailored treatment options for patients with psoriatic arthritis and psoriasis: review of established and new biologic and small molecule therapies. *Rheumatol Int* 2016; 36: 603–612.
  40. Reich K, Nestle FO, Papp K, Ortonne JP, Evans R, Guzzo C, et al. Infliximab induction and maintenance therapy for moderate-to-severe psoriasis: a phase III, multicentre, double-blind trial. *Lancet* 2005; 366: 1367–1374.
  41. Kalb RE, Blauvelt A, Sofen HL, Chevrier M, Amato D, Calabro S, et al. Effect of infliximab on health-related quality of life and disease activity by body region in patients with moderate-to-severe psoriasis and inadequate response to etanercept: results from the PSUNRISE trial. *J Drugs Dermatol* 2013; 12: 874–880.
  42. Ortonne JP, Paul C, Berardesca E, Marino V, Gallo G, Brault Y, et al. A 24-week randomized clinical trial investigating the efficacy and safety of two doses of etanercept in nail psoriasis. *Br J Dermatol* 2013; 168: 1080–1087.
  43. Luger TA, Barker J, Lambert J, Yang S, Robertson D, Foehl J, et al. Sustained improvement in joint pain and nail symptoms with etanercept therapy in patients with moderate-to-severe psoriasis. *J Eur Acad Dermatol Venereol* 2009; 23: 896–904.
  44. Crowley JJ, Weinberg JM, Wu JJ, Robertson AD, Van Voorhees AS, National Psoriasis Foundation. Treatment of nail psoriasis: best practice recommendations from the Medical Board of the National Psoriasis Foundation. *JAMA Dermatol* 2015; 151: 87–94.
  45. Leonardi C, Langley RG, Papp K, Tying SK, Wasel N, Vender R, et al. Adalimumab for treatment of moderate to severe chronic plaque psoriasis of the hands and feet: efficacy and safety results from REACH, a randomized, placebo-controlled, double-blind trial. *Arch Dermatol* 2011; 147: 429–436.
  46. Elewski BE, Okun MM, Papp K, Baker CS, Crowley JJ, Guillet G, et al. Adalimumab for nail psoriasis: Efficacy and safety from the first 26 weeks of a phase 3, randomized, placebo-controlled trial. *J Am Acad Dermatol* 2018; 78: 90–99 e91.
  47. Van den Bosch F, Manger B, Goupille P, McHugh N, Rødevand E, Holck P, et al. Effectiveness of adalimumab in treating patients with active psoriatic arthritis and predictors of good clinical responses for arthritis, skin and nail lesions. *Ann Rheum Dis* 2010; 69: 394–399.
  48. Rigopoulos D, Gregoriou S, Lazaridou E, Belyayeva E, Apalla Z, Makris M, et al. Treatment of nail psoriasis with adalimumab: an open label unblinded study. *J Eur Acad Dermatol Venereol* 2010; 24: 530–534.
  49. Cohen Barak E, Kerner M, Rozenman D, Ziv M. Combination therapy of cyclosporine and anti-tumor necrosis factor alpha in psoriasis: a case series of 10 patients. *Dermatol Ther* 2015; 28: 126–130.
  50. Mease PJ, Fleischmann R, Deodhar AA, Wollenhaupt J, Khraishi M, Kielar D, et al. Effect of certolizumab pegol on signs and symptoms in patients with psoriatic arthritis: 24-week results of a Phase 3 double-blind randomised placebo-controlled study (RAPID-PsA). *Ann Rheum Dis* 2014; 73: 48–55.
  51. Kavanaugh A, McInnes I, Mease P, Krueger GG, Gladman D, Gomez-Reino J, et al. Golimumab, a new human tumor necrosis factor alpha antibody, administered every four weeks as a subcutaneous injection in psoriatic arthritis: Twenty-four-week efficacy and safety results of a randomized, placebo-controlled study. *Arthritis Rheum* 2009; 60: 976–986.
  52. Kyriakou A, Patsatsi A, Sotiriadis D. Anti-TNF agents and nail psoriasis: a single-center, retrospective, comparative study. *J Dermatol Treat* 2013; 24: 162–168.
  53. Rich P, Bourcier M, Sofen H, Fakhrazadeh S, Wasfi Y, Wang Y, et al. Ustekinumab improves nail disease in patients with moderate-to-severe psoriasis: results from PHOENIX 1. *Br J Dermatol* 2014; 170: 398–407.
  54. Bardazzi F, Antonucci VA, Tengattini V, Odorici G, Balestri R, Patrizi A. A 36-week retrospective open trial comparing the efficacy of biological therapies in nail psoriasis. *J Dtsch Dermatol Ges* 2013; 11: 1065–1070.
  55. Langley RG, Rich P, Menter A, Krueger G, Goldblum O, Dutronc Y, et al. Improvement of scalp and nail lesions with ixekizumab in a phase 2 trial in patients with chronic plaque psoriasis. *J Eur Acad Dermatol Venereol* 2015; 29: 1763–1770.
  56. Dennehy EB, Zhang L, Amato D, Goldblum O, Rich P. Ixekizumab is effective in subjects with moderate to severe plaque psoriasis with significant nail involvement: results from UNCOVER 3. *J Drugs Dermatol* 2016; 15: 958–961.
  57. Armstrong AW, Vender R, Kircik L. Secukinumab in the treatment of palmoplantar, nail, scalp, and pustular psoriasis. *J Clin Aesthet Dermatol* 2016; 9: S12–S16.
  58. Papp K, Cather JC, Rosoph L, Sofen H, Langley RG, Matheson RT, et al. Efficacy of apremilast in the treatment of moderate to severe psoriasis: a randomized controlled trial. *Lancet* 2012; 380: 738–746.
  59. Merola JF, Elewski B, Tatulych S, Lan S, Tallman A, Kaur M. Efficacy of tofacitinib for the treatment of nail psoriasis: two 52-week, randomized, controlled phase 3 studies in patients with moderate-to-severe plaque psoriasis. *J Am Acad Dermatol* 2017; 77: 79–87.e1.