



## Pleural Fluid Eosinophilia: A Possible Adverse Event of Interleukin-17 Inhibition

Wakiko HAYASHI<sup>1</sup>, Shin-Ichi OSADA<sup>1\*</sup>, Aya TOYOSHIMA<sup>1</sup>, Katsuhiko YAMADA<sup>1</sup>, Kazuhisa SUDO<sup>2</sup>, Katsutoshi NAKAYAMA<sup>2</sup> and Motomu MANABE<sup>1</sup>

<sup>1</sup>Department of Dermatology & Plastic Surgery, and <sup>2</sup>Department of Respiratory Medicine, Akita University Graduate School of Medicine, Hondo 1-1-1, Akita 010-8543, Japan. \*E-mail: osada0130@gipc.akita-u.ac.jp

Accepted Sep 10, 2019; E-published Sep 10, 2019

Brodalumab, a human monoclonal anti-interleukin (IL)-17 receptor A antibody, is used to treat patients with moderate-to-severe plaque psoriasis in the USA and Europe. In Japan it is also indicated for use in treatment of pustular psoriasis and psoriatic erythroderma (1). Common side-effects of brodalumab include headache, arthralgia, myalgia, fatigue, diarrhoea, superficial fungal infections, and neutropaenia. We report here a case of pustular psoriasis complicated with pleural fluid eosinophilia (PFE) following the consecutive administration of brodalumab.

### CASE REPORT

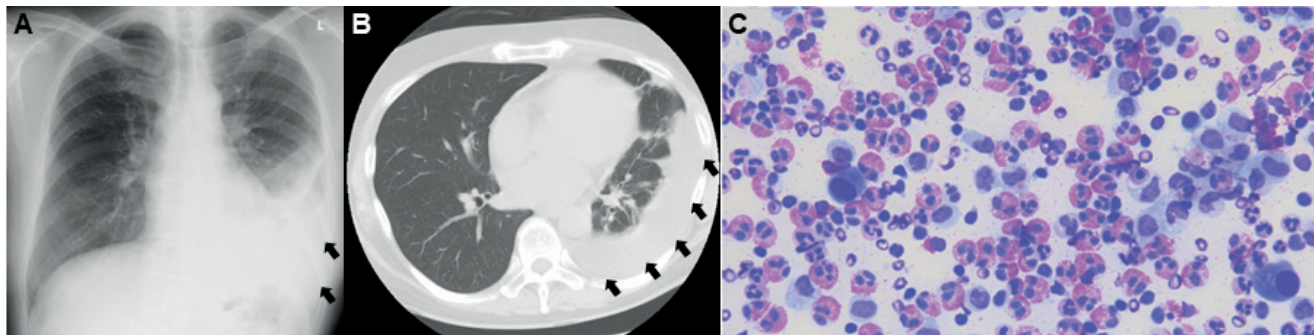
A man in his 40s presented in the emergency department with a 2-day history of left-side chest pain. He had a history of pustular psoriasis for more than 30 years and had been treated with topical glucocorticoids, oral immunosuppressive agents, and infliximab for the last 7 years. Although his psoriatic lesions were stable with infliximab, because of the inconvenience of intravenous injections every 4 weeks his treatment was switched from infliximab to brodalumab. Psoriasis Area and Severity Index 100 was achieved after 2 injections of brodalumab. The patient received brodalumab 16 times before the development of respiratory symptoms. X-ray and computed tomography (CT) of the chest revealed a pleural effusion in the left lower lung field, leading to a diagnosis of pleuritis. The patient returned home after being prescribed an antibiotic.

Four days later he was admitted to respiratory medicine because of deterioration of respiratory symptoms and an increased pleural effusion on X-ray (Fig. 1A) and

CT (Fig. 1B). Laboratory findings revealed leukocytosis (9,200 cells/l; reference range: 3,300–8,600 cells/l) with eosinophilia (12%; reference range: 2–6.8%) and an elevated C-reactive protein level (10.17 mg/l; reference range: <0.14 mg/l). Image findings and negative test results for blood and sputum cultures, interferon- $\gamma$  release assay, autoantibodies, tumour markers, antibodies for mycoplasma, *Aspergillus*, and *Cryptococcus* ruled out interstitial pneumonia, bacterial and fungal infections, lung cancer, tuberculosis, and collagen diseases. Cytopathological examination of the pleural effusion revealed massive infiltration of eosinophils (Fig. 1C). A diagnosis of PFE was made and chest drainage was performed, resulting in improvement in the patient's clinical symptoms and laboratory findings. Because the interruption of brodalumab exacerbated the patient's psoriatic skin lesions, secukinumab, a human monoclonal antibody to IL-17A, was introduced. However, pleural effusion in the left lower lung field appeared again after the 5<sup>th</sup> administration of secukinumab. Resumption of infliximab resolved his skin lesions and respiratory symptoms.

### DISCUSSION

PFE is defined as pleural fluid with a nucleated cell count containing more than 10% eosinophils (2, 3). In a meta-analysis of 687 cases of PFE, the most common causes were malignancy (26%) followed by idiopathic (25%) and parapneumonic (13%) (4). Drug-induced PFE is not so common and approximately 25 drugs have been implicated in the development of PFE, and concomitant peripheral blood eosinophilia is sometimes present



**Fig. 1.** (A) X-ray and (B) computed tomography (CT) images of the patient on admission revealed pleural effusion in the left lower lung field. (C) Cytopathological examination of the pleural effusion demonstrated massive infiltration of eosinophils (Giemsa stain;  $\times 1,000$ ). Arrows in (A) and (B) indicate pleural effusion.

(5). Symptoms of drug-induced PFE are non-specific and include pleuritic chest pain, cough, dyspnoea, and occasional fever (5, 6). Although we cannot rule out the possibility that the patient's PFE was caused by an idiopathic mechanism or other unidentified infectious agents, we speculate that brodalumab was primarily involved in his PFE.

In general, drug-induced PFE lung affection occurs unilaterally approximately several months after taking the causative medicine (5, 6), consistent with our patient's clinical courses. Although the patient continued taking medications for hypertension, hyperuricemia, and arthralgia after the PFE was resolved, no recurrence of his respiratory symptoms was observed, suggesting that these medications were not causative agents. Most importantly, administration of secukinumab recapitulated pleural effusion, providing further evidence that anti-IL-17 pathway agents can cause PFE.

Pathogenesis of the anti-IL-17-induced PFE is unknown. Because lung and pleural tissue do not normally harbour eosinophils, the development of PFE requires the recruitment of bone marrow derived eosinophils and cytokines, chemokines, and adhesion molecules are implicated in this process (5, 7). It has been reported that Th2 and Th17 inflammatory pathways are reciprocally regulated in asthma: in bronchial epithelial cells, IL-13 stimulation represses the expression of Th17 genes, whereas IL-17A stimulation represses the expression of Th2 genes (8). Thus, it may be possible that downregulation of the Th17 pathway by consecutive administration

of brodalumab conversely stimulated Th2 genes to induce eosinophilia via Th2 cytokine production.

Because both brodalumab (primarily) and secukinumab (secondarily) induce PFE in the patient, PFE may be a late class effect of anti-IL-17A blockade. Considering that the number of psoriatic patients treated with brodalumab is increasing worldwide, the current case provides useful information regarding patient safety.

## REFERENCES

1. Yamasaki K, Nakagawa H, Kubo Y, Ootaki K. Efficacy and safety of brodalumab in patients with generalized pustular psoriasis and psoriatic erythroderma: results from a 52-week, open-label study. *Br J Dermatol* 2017; 176: 741–751.
2. Hirsch A, Ruffie P, Nebut M, Bignon J, Chrétien J. Pleural effusion: laboratory tests in 300 cases. *Thorax* 1979; 34: 106–112.
3. Kalomenidis I, Light RW. Eosinophilic pleural effusions. *Curr Opin Pulm Med* 2003; 9: 254–260.
4. Oba Y, Abu-Salah T. The prevalence and diagnostic significance of eosinophilic pleural effusions: a meta-analysis and systematic review. *Respiration* 2012; 83: 198–208.
5. Huggins JT. Pleural fluid eosinophilia. Post TW, ed. UpToDate [accessed 2019 April 11]. Waltham, MA: UpToDate Inc. Available from: <http://www.uptodate.com>.
6. Huggins JT, Sahn SA. Drug-induced pleural disease. *Clin Chest Med* 2004; 25: 141–153.
7. Heidecker J, Kaplan A, Sahn SA. Pleural fluid and peripheral eosinophilia from hemothorax: hypothesis of the pathogenesis of EPE in hemothorax and pneumothorax. *Am J Med Sci* 2006; 332: 148–152.
8. Choy DF, Hart KM, Borthwick LA, Shikotra A, Nagarkar DR, Siddiqui S, et al. TH2 and TH17 inflammatory pathways are reciprocally regulated in asthma. *Sci Transl Med* 2015; 7: 301ra129.