

## Atypical Varicella-zoster Infection in AIDS

B. LØKKE JENSEN<sup>1</sup>, K. WEISMANN<sup>1</sup>, L. MATHIESEN<sup>3</sup> and H. KLEM THOMSEN<sup>2</sup>

Departments of <sup>1</sup>Dermato-Venereology and <sup>2</sup>Pathology, Bispebjerg Hospital, Copenhagen and <sup>3</sup>Department of Infectious Diseases, Hvidovre Hospital, Hvidovre, Denmark

**A case of atypical varicella zoster in a 33-year-old AIDS patient is reported. The patient had had two attacks of herpes zoster within a year and was given high-dose acyclovir several times. Thereafter he developed small keratotic pellucid papules on fingers, wrists and face, which were found to contain varicella-zoster antigen by the ELISA test. Skin biopsy showed acanthosis and lack of vesication, as is usually seen in herpes infections. The atypical varicella-like lesions persisted despite repeated doses of acyclovir but cleared temporarily when the patient was given foscarnet. We believe that the prolonged therapy may have allowed selection of acyclovir-resistant varicella-zoster strains, resulting in the atypical clinical course. Key words: Acyclovir; Herpes zoster-varicella virus.**

(Accepted October 5, 1992.)

Acta Derm Venereol (Stockh) 1993; 73: 123-125.

B. Løkke Jensen, Department of Dermato-Venereology, Bispebjerg Hospital, Copenhagen, Denmark.

Herpes zoster occurs among HIV-infected individuals at an incidence about seven times greater than in the general population (1). The eruption often occurs as an early sign of compromised immune function, which makes it an important indicator of HIV infection among younger individuals. The clinical presentation of herpes zoster in HIV-infected patients is often typical with a dermatomal distribution, but some patients experience recurrent attacks (2, 3). Recently atypical forms of varicella-zoster virus (VZV) infection in HIV-positive patients have been reported. Nodular, pox-like, hyperkeratotic or necrotic skin lesions in AIDS patients receiving pro-

longed treatment with acyclovir have been described by Linne-mann et al. (4), Disler & Dover (5) and Hoppenjans et al. (6).

In our clinic we have seen an AIDS patient with persistent atypical VZV with features different from earlier reports.

### CASE REPORT

The patient was a 33-year-old man with AIDS, probably HIV-infected in 1985 with previous lymphadenopathy syndrome and *Pneumocystis carinii* lung infection. He had lost weight and had showed a decreasing CD4-cell count from  $147 \times 106/l$  to  $36 \times 106/l$  within the last 3 years.

From October 1989 the patient received isoprinosine, as zidovudine treatment was not tolerated. Since June 1989 he had had two episodes of classic thoracic herpes zoster treated with acyclovir 800 mg 5 times daily for several periods. The patient several times initiated treatment himself; thus the total number of treatment days cannot be stated. From July 1990 he developed persistent eruptions of small, millimeter-sized hyperkeratotic pellucid papules on hands, fingers, arms and face (Figs. 1-2). The elements did not ulcerate or crust at any time. He was treated with oral acyclovir 800 mg 5 times daily for 20 days; then he was given repeated courses of intravenous acyclovir 750 mg 3 times daily for more than 10 days without any clinical effect.

Biopsies from the elements on the wrist showed a slightly folded surface. Epidermis was acanthotic and small areas with lysis of keratinocytes were observed, but vesication, usual in herpes infections, did not occur (Fig. 3). Within the affected area many cells in epidermis showed a "ground-glass" appearance of the nuclear chromatin and some contained large eosinophilic nuclear inclusion-bodies (Fig. 4). Similar nuclear changes were observed in a few endothelial cells in vessels just below the affected part of epidermis. Morphologically the findings were consistent with a HSV or a VZV infection. Immunohistological studies of the biopsies with antibodies to HSV type 1 and 2 (Dako Laboratories, Glostrup, Denmark) were negative.

The varicella-zoster antigen ELISA test was positive but the herpes

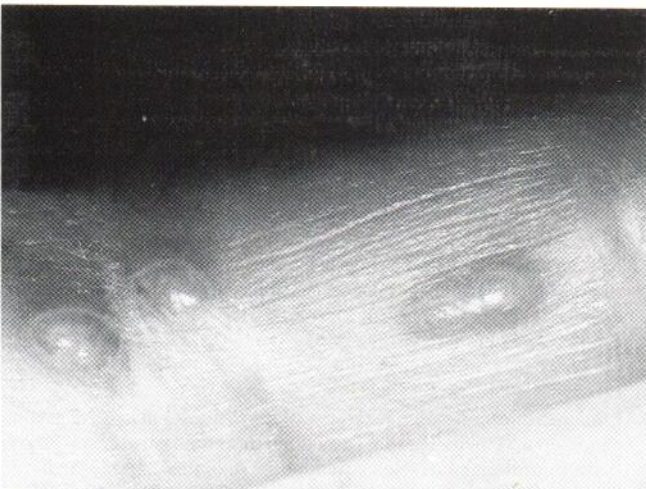

Fig. 1. Hyperkeratotic pellucid atypical varicella-zoster lesions on a finger.

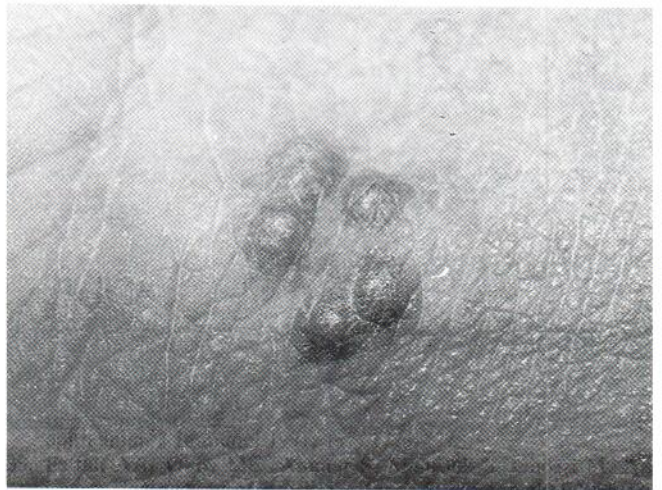

Fig. 2. A cluster of hyperkeratotic papules on the wrist.

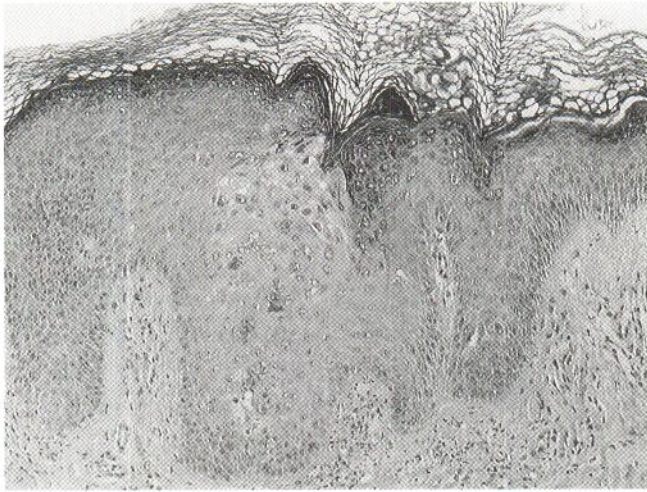


Fig. 3. The surface appears slightly folded and the epithelium is acanthotic. In the central part a small, pale staining area is present superficially in stratum spinosum. HE. Primary magnification  $\times 100$ .

simplex type 1 & 2 ELISA test was negative from vigorously scrapings with a scalpel from keratotic elements on the wrist. Both the ELISA tests were performed at State Serum Institute, Copenhagen, Denmark, as a sandwich ELISA method with HSV antibodies from Dako Laboratories, Glostrup, Denmark, and biotinylated rabbit IgG antibodies specific against VZV were developed at State Serum Institute, Copenhagen, Denmark. The varicella-zoster antibody in serum was low. As no effect was seen of the repeatedly administered acyclovir, resistance against the antiviral agent was suspected. Repeated cultures for VZV from the patient's skin lesions were unsuccessful, and thus no resistance testing against acyclovir could be demonstrated. During subsequent hospitalization the patient was treated with i.v. foscarnet 4 g 3 times daily for 14 days and regression of the skin symptoms were seen but they reappeared 18 days after cessation of treatment. The treatment was reintroduced but soon after the patient developed a disseminated infection with *S. aureus* and died.

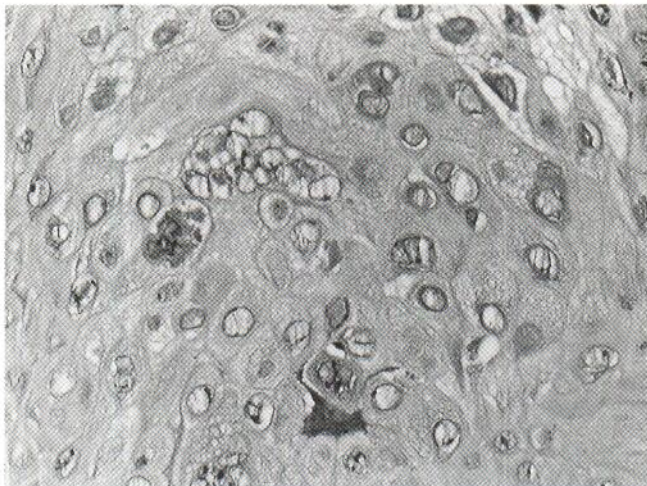


Fig. 4. Part of stratum spinosum. Many cells have nuclei with "ground-glass"-appearance and some contain nuclear inclusion-bodies. Several giant cells are present. There is no vesication. HE. Primary magnification  $\times 100$ .

## DISCUSSION

Varicella results from infection of a non-immune host with varicella-zoster virus and herpes zoster is caused by reactivation of a dormant VZV infection in a partially immune host. In the immune-competent patient the classical segmental eruption along a sensory nerve develops, whereas in immune-compromised patients, as typically seen in late HIV infections, atypical recurring lesions may occur. Janier et al. (3) described chronic pox-like ulcerations of two months' duration in a 27-year-old HIV-positive man. Acyclovir failed to control the disease and VZV was tested and appeared to be resistant to acyclovir.

Peronne et al. (7) described dissemination of VZV lesions in HIV-seropositive patients. In a retrospective study, 15 of 421 patients developed varicella, 12 cases with a typical course and 3 patients with atypical forms, described as disseminated cutaneous pox-like lesions. One of the patients experienced three relapses of atypical varicella. The 3 patients had positive VZV serology before the eruption.

Gilson et al. (8) reported the development of ecthymatous persistent skin lesions in 3 patients with AIDS. Two of them had a vesicular dissemination; all responded well to acyclovir therapy. Hoppenjans et al. (6) and Linnemann et al. (4) reported the appearance of acyclovir resistance against VZV strains isolated from AIDS patients. The lesions were described as large, hyperkeratotic and verrucous, different from the small pellucid papular elements of our patient. The inability to mount an effective cell-mediated immune response contributed to the prolonged course of the eruption (6).

We did not succeed in culturing VZV from our patient and therefore we were not able to demonstrate a possible decreased sensitivity to acyclovir. It is believed that a prolonged regimen with inadequate doses of acyclovir may allow selection of resistant VZV strains (4-6), and we believe that this was the cause of the atypical clinical presentation. It is advisable to treat AIDS patients with high-dose intravenous acyclovir (10 mg/kg every 8 h) whenever possible and for longer than the usual 7 days (4, 6). Our patient responded favourably to foscarnet, which has been proven effective in AIDS patients with resistant herpes simplex virus (9).

## REFERENCES

1. Friedman-Kien AE, LaFleur FL, Gender E, et al. Herpes zoster: a possible early sign for development of acquired immunodeficiency syndrome in high-risk individuals. *J Am Acad Dermatol* 1986; 14: 1023-1028.
2. Kaplan MH, Sadick N, Scott McNutt N, et al. Dermatologic findings and manifestations of acquired immunodeficiency syndrome (AIDS). *J Am Acad Dermatol* 1987; 16: 485-506.
3. Janier M, Hillion B, Baccard M, et al. Chronic varicella-zoster infection in acquired immunodeficiency syndrome. *J Am Acad Dermatol* 1988; 18: 584-585.
4. Linnemann CC, Biron KK, Hoppenjans WG, Solinger AM. Emergence of acyclovir-resistant varicella-zoster virus in an AIDS patient on prolonged acyclovir therapy. *AIDS* 1990; 4: 577-579.
5. Disler RS, Dover JS. Chronic localized herpes zoster in AIDS. *Arch Dermatol* 1990; 126: 1105-1106.
6. Hoppenjans WB, Bibler MR, Orme RL, Solinger AM. Prolonged

- cutaneous herpes zoster in acquired immunodeficiency syndrome. *Arch Dermatol* 1990; 126: 1048–1050.
7. Perronne C, Lazanas M, Lepout C, et al. Varicella in patients infected with the human immunodeficiency virus. *Arch Dermatol* 1990; 126: 1033–1036.
  8. Gilson JH, Barnett JH, Conant MA, et al. Disseminated ecthymatous herpes varicella-zoster virus infection in patients with acquired immunodeficiency syndrome. *J Am Acad Dermatol* 1989; 20: 637–642.
  9. Sall RK, Kauffman CL, Levy CS. Successful treatment of progressive acyclovir-resistant herpes simplex virus using intravenous foscarnet in a patient with the acquired immunodeficiency syndrome. *Arch Dermatol* 1989; 125: 1548–1550.