

Inflammatory Carcinoma Masquerading as Erythema Annulare Centrifugum

MARTIN REICHEL and RONALD G. WHEELAND

Department of Dermatology, University of California, Davis, Sacramento, California, USA

A case of inflammatory carcinoma, or carcinoma erysipelatodes, clinically resembling erythema annulare centrifugum is reported. The cutaneous inflammatory carcinoma was due to metastasis by a signet-ring cell adenocarcinoma, probably of gastrointestinal origin. This is the third reported case of inflammatory carcinoma with signet-ring cell infiltration. Cancer patients with atypical or unusual inflammatory dermatoses should be evaluated by skin biopsy because of the possible association with the internal neoplastic process. Key word: Metastatic inflammatory carcinoma.

(Accepted November 10, 1992.)

Acta Derm Venereol (Stockh) 1993; 73: 138–140.

R. G. Wheeland, Department of Dermatology, University of California, Davis, 1700 Alhambra Boulevard, # 200, Sacramento, California 95816, USA.

The association of cutaneous metastasis with clinical signs of inflammation was first described by Küttner in 1924 and designated "erysipelas carcinomatosum" (1). In 1931, Rasch suggested the name "carcinoma erysipelatodes acutum", to emphasize the acute, inflammatory appearance of the lesions (2). Carcinoma erysipelatodes, or inflammatory carcinoma, is clinically characterized by the development of red, warm, indurated cutaneous plaques suggesting an acute inflammatory process, such as cellulitis. On histopathology there is lymphatic spread of tumor cells within the dermis.

CASE REPORT

A 32 year-old white man reported swelling of the left groin for 1 year and progressive left leg lymphedema of several months' duration. There was no history of smoking or alcohol use. On physical examination, left lower extremity edema and two firm palpable inguinal lymph nodes were noted. Significant laboratory evaluation showed an albumin of 3.3 g/dl, a carcinoembryonic antigen (CEA) of less than 1 ng/ml and nondetectable levels of both human chorionic gonadotropin (HCG) and α -fetoprotein (AFP). Computed axial tomography demonstrated enlarged inguinal nodes, a 2 cm hemangiomas liver lesion in the left lobe, bilateral hydroceles, and a partially undescended atrophic left testicle. Doppler ultrasound of the lower extremities showed no evidence of deep vein thrombosis. The diagnosis of lymphedema praecox or Milroy's disease was considered, and a lymphangiogram was performed which demonstrated no filling proximal to the inguinal area.

The patient's lymphedema became progressively worse and 10 months later axillary lymph nodes were noted. Magnetic resonance imaging at that time showed small bilateral pleural effusions, bilateral hydroceles and persistence of the hepatic lesion, but no lymphadenopathy. Serum HCG was increased at 7.8 mciu/ml, but CEA was less than 1 ng/ml. A left axillary lymph node biopsy demonstrated signet-

ring cell adenocarcinoma that stained positively for mucin with alcian blue. In addition, immunoperoxidase cell markers were positive for both CEA and HCG, but negative for AFP. Air contrast barium enema and upper gastrointestinal series with small bowel follow-through were both negative.

While tumor histology was that of an adenocarcinoma, because of positive staining for HCG, elevated serum HCG, and lymph node metastasis in association with the finding of a partially undescended left testicle, a germ cell neoplasm was suggested. Whereas adenocarcinoma of unknown primary responds poorly to treatment and has a poor prognosis, cis-platinum-based chemotherapy for germ cell tumors may achieve long-term disease free intervals. With this presumptive diagnosis, the patient was given 2 cycles of PEB (cis-platinum 20 mg/m² \times 5 days, etoposide 100 mg/m² \times 5 days, bleomycin 30 Units IV). When the enlarged lymph nodes did not significantly decrease in size following this treatment protocol, he was considered a treatment failure and given 1 cycle of FAM (mitomycin 10 mg/m², adriamycin 30 mg/m², 5-fluorouracil 600 mg/m²).

At the time of our initial examination 2 months later, pertinent physical findings included generalized edema, enlarged supraclavicular and axillary lymph nodes, and on the lower extremities multiple annular and polycyclic blanchable, erythematous plaques with a trailing rim of scale (Fig. 1). These plaques were confluent on the abdomen but did not progress further in size. The clinical differential diagnoses included erythema annulare centrifugum and erythema gyratum repens. An excisional biopsy was performed of a representative lesion from the left medial calf. Histopathology revealed numerous aggregates of neoplastic cells within the lymphatic channels of the superficial and deep dermis (Fig. 2). Signet-ring cells were present. The neoplastic cells were characterized by lumina formation. An alcian blue stain demonstrated marked accumulation of intracellular mucin within the signet-ring cells. These findings substantiated a diagnosis of inflammatory metastatic signet-ring cell adenocarcinoma.

Subsequently, computed axial tomography of the chest showed a 2.5 cm left axillary node and a small left pleural effusion. An axillary lymph node biopsy of the enlarged node revealed the continued presence of foci of adenocarcinoma. Despite the fact that the patient was given 2 courses of cis-platinum 50 mg/m² and etoposide 150 mg/m² over the next 2 months, there was no change in the skin lesions, the pleural effusions worsened, and the patient died 1 month later.

DISCUSSION

Inflammatory carcinoma is a rare form of cutaneous metastasis by an internal carcinoma with localization to the superficial lymphatic system. This results in the development of erythematous, circinate plaques that may clinically resemble an acute infectious process, such as cellulitis or erysipelas. Lesions of carcinoma erysipelatodes are due to capillary congestion from retrograde tumor spread and subsequent lymphatic obstruction within the dermis, panniculus, deep lymphatics and lymph nodes, resulting in lymphedema.

The term inflammatory carcinoma is misleading in that these lesions are not composed of a significant inflammatory infiltrate. The most common cause of inflammatory carcinoma

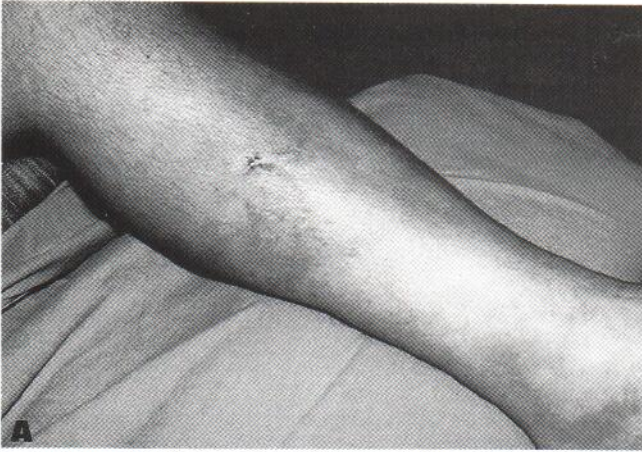
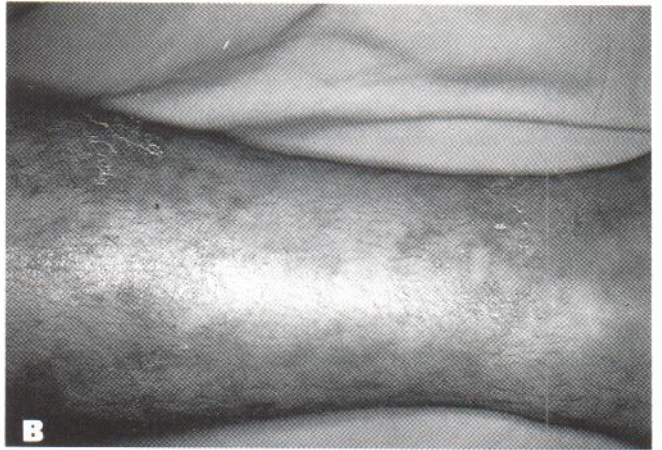

Fig. 1. Annular erythematous plaque of inflammatory carcinoma.



is breast carcinoma; yet this form of metastasis occurs in only 1–4% of these cases (3). Such spread has also been reported in carcinomas of the lung (4, 5), pancreas (6), stomach (7–9), rectum (10), cervix (11, 12), parotid gland (13), ovaries (14), as well as with melanoma (15). Our patient is the third reported case of inflammatory carcinoma with signet-ring cell infiltration (8, 9).

Inflammatory carcinoma characteristically has a circinate morphology with the most common pattern being a well-circumscribed, warm, red, indurated plaque. Ingram (4) has noted that in carcinoma erysipelatodes secondary to breast carcinoma, ringed plaques with a centrifugal pattern of spread are common. This unique morphology is correctly attributed

to tumor spread being restricted to vascular zones, and not direct penetration of the tissue by metastatic tumor cells. This mechanism may also account for the annular, crescentic, ringed, and polycyclic lesions seen in the cutaneous lymphoma, mycosis fungoides.

Erythema gyratum repens, erythema annulare centrifugum and necrolytic migratory erythema all have variable associations with internal malignancy. The paraneoplastic gyrate erythemas may be partially due to the abnormal patterns of lymphatic and vascular drainage secondary to tumor infiltration of these structures.

Because of the findings in our patient, we recommend that metastatic carcinoma be included in the differential diagnosis

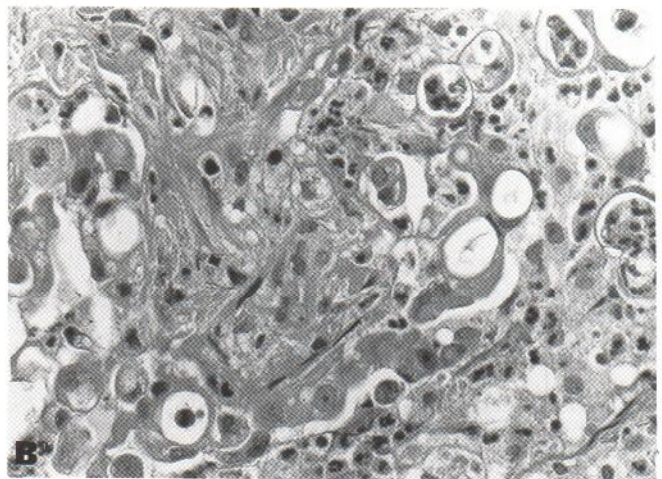
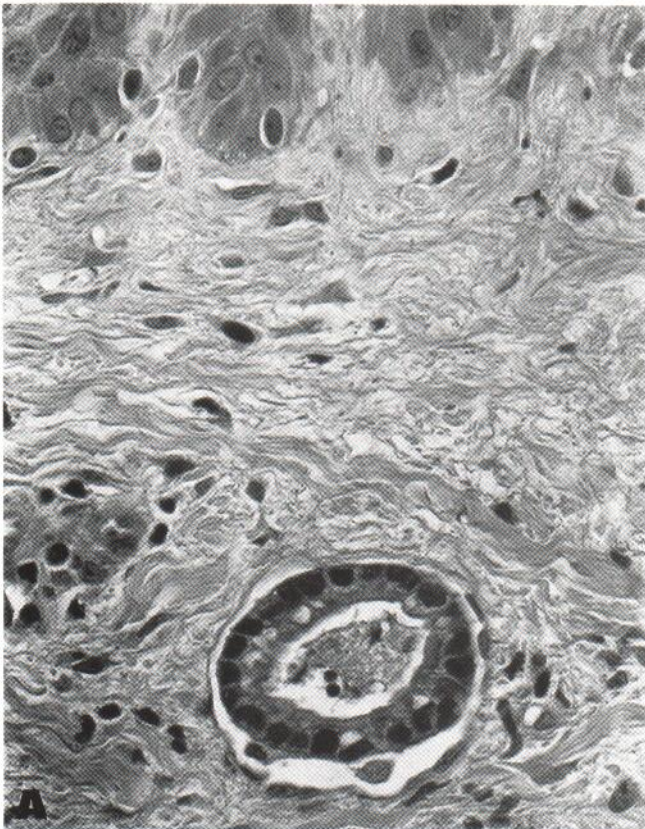


Fig. 2. Dilated superficial lymphatic space with lumina formation by signet-ring cells. Dermal collection of pleomorphic cells and cells characterized by enlarged, clear cytoplasmic space with eccentrically placed nuclei (hematoxylin and eosin, original magnification $\times 40$).

of figurate erythemas. Proven evidence of cutaneous spread may change both the prognosis and treatment of the these patients, since it represents distant metastasis. This is especially significant in our patient because signet-ring cell carcinoma carries a much worse prognosis than other gastrointestinal carcinomas, commonly developing a decade earlier in life than other colorectal carcinomas (16). Furthermore, the diagnosis of signet-ring cell carcinoma may be delayed because gastrointestinal carcinoma is relatively rare and does not commonly occur in young people. For these reasons, patients with signet-ring cell adenocarcinoma commonly present with late stage disease (16). In a similar case, an ovarian carcinoma which had metastasized to the abdominal wall was clinically felt to be erythema annulare centrifugum but on biopsy demonstrated lymphatic tumor spread (17). In patients with suspected or proven cancer, atypical or unusual inflammatory dermatoses may, in fact, be neoplastic in origin.

REFERENCES

1. Küttner H. Beiträge zur Pathologie des Mammacarcinoms. *Beitr Klin Chir* 1924; 131: 1-9.
2. Rasch C. Carcinoma erysipelatodes. *Br J Dermatol Syphilol* 1931; 43: 351-354.
3. Kramer A, Buzdar AU. Inflammatory breast carcinoma. *Am J Clin Oncol* 1986; 9: 541-543.
4. Ingram JT. Carcinoma erysipelatodes and carcinoma telangiectaticum. *Arch Dermatol* 1958; 77: 227-231.
5. Hazelrigg DE, Rudolph AH. Inflammatory metastatic carcinoma. *Arch Dermatol* 1977; 113: 69-70.
6. Edelstein JM. Pancreatic carcinoma with unusual metastasis to the skin and subcutaneous tissue simulating cellulitis. *N Engl J Med* 1950; 242: 779-781.
7. Moutier F, Marre L. Envahissement du sein au cours de la généralisation lymphatique étendue d'un cancer colloïde massif de l'estomac chez une femme de 31 ans. Variété histologique particulière d'épithélioma gastrique. *Arch Med Exper Anat Pathol* 1910; 22: 433-461.
8. Choi HM, Myung KB, Kook HI. Cutaneous metastatic adenocarcinoma of the stomach: nodular and inflammatory carcinoma. *J Korean Med Sci* 1986; 1: 49-52.
9. Bertani E, Tamborini M, Veraldi S. Atypical cutaneous metastases from signet-ring cell gastric carcinoma. *Skin Cancer* 1988; 3: 111-115.
10. Reuter MJ, Nomland R. Inflammatory cutaneous metastatic carcinoma. *Wis Med J* 1941; 40: 196-201.
11. Zala L, Jenni C. Das carcinomas erysipelatodes. *Dermatologica* 1980; 160: 80-89.
12. Freeman CR, Rozenfeld M, Schopflicher P. Cutaneous metastases from carcinoma of the cervix. *Arch Dermatol* 1982; 118: 40-41.
13. Schwartz RA, Rubenstein DJ, Raventios A, Lambert WC. Inflammatory metastatic carcinoma of the parotid. *Arch Dermatol* 1984; 120: 796-797.
14. Krishnan EU, Phillips AK, Randell A, Taylor B, Garg SK. Bilateral inflammatory carcinoma in the breast from primary ovarian cancer. *Obstet Gynecol* 1980; 55 (3 Suppl): 94S-96S.
15. Haupt HM, Hood AF, Cohen MH. Inflammatory melanoma. *J Am Acad Dermatol* 1984; 10: 52-55.
16. Kirkham N. Colorectal signet ring cell carcinoma in young people. *J Pathol* 1988; 155: 93-94.
17. Bernecker HA, Bachmann W. Hautmetastasen eines Ovarialkarzinoms unter dem Bild eines erythema annulare. *Hautarzt* 1979; 30: 164-165.