

# Primary Leiomyosarcoma of the Skin

## A Histological and Immunohistochemical Analysis

DIRK SCHADENDORF, NORBERT HAAS, HERMANN OSTMEIER and BEATE M. CZARNETZKI

Department of Dermatology, Clinical Immunology and Asthma, University Hospital Rudolf Virchow, Free University of Berlin, Germany

We report a rare case of a cutaneous leiomyosarcoma on the extensor surface of the proximal part of the left arm of an 84-year-old man. The tumour exhibited a number of histological and immunohistochemical features which are characteristic of a leiomyosarcoma. Leiomyosarcomas are frequently misdiagnosed on clinical grounds. Therefore, clinical features, differential diagnosis, histological and immunohistochemical criteria, therapy and prognosis of this rare malignant tumour are summarized on the basis of the present case and previously published reports. **Key words:** Immunohistochemistry; Differential diagnosis; Soft tissue sarcoma.

(Accepted November 30, 1992.)

Acta Derm Venereol (Stockh) 1993; 73: 143-145.

D. Schadendorf, University Hospital Rudolf Virchow, Department of Dermatology, FU Berlin, Augustenburger Platz 1, 1000 Berlin 65, Germany.

Leiomyosarcomas are malignant non-epithelial tumours. They derive from smooth muscle cells of vessels, predominantly in visceral locations such as the uterus, the gastrointestinal tract, the mesentery, the urogenital system or the retroperitoneal space (1-3). Leiomyosarcomas of the dermis and subcutaneous tissues are rare, accounting for less than 5% of all soft tissue sarcomas in adults (1-6). Cutaneous leiomyosarcomas are believed to derive from the erector pili muscles, smooth muscles that surround sweat glands in the nearby adipose tissue at or below the junction of the cutis and subcutis or from vascular tissue (1, 4).

In this report, we describe the histological and immunohistochemical features of a rare case of a subcutaneous leiomyosarcoma in an elderly man.

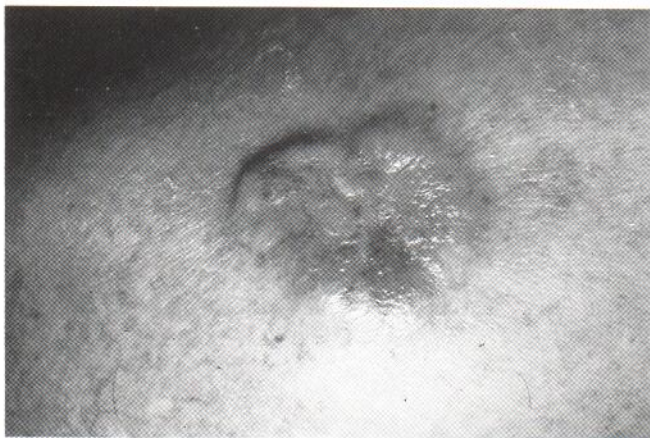

Fig. 1. Clinical aspect of tumour on hospital admission.

### CASE REPORT

#### History

An 84-year-old man was admitted to the hospital, complaining of a tumour at his left shoulder which had grown over the last 6 weeks and caused pain, especially when he was lying on it at night. The patient could not remember any trauma in that region before the development of the tumour.

#### Physical examination

The examination showed a solitary, elevated, umbilicated skin lesion over the left deltoid muscle (Fig. 1). There were no signs of irritation or inflammation, but a few telangiectatic vessels were visible. The indurated tumour was movable over the fascia, whereas the overlying skin seemed to be attached to the tumour. No ulceration was visible. The patient complained of extensive pain during manipulation of the tumour. There was no significant lymphadenopathy. Other notable findings included a co-existing diabetes mellitus, emphysema and erythrasma of both axillae.

#### Laboratory findings on admission

Routine laboratory findings disclosed no abnormalities except for a small increase of cholesterol and triglycerides. Electrocardiography revealed an absolute tachyarrhythmia. An ultrasound investigation of the abdomen and lymphnodes, computer tomography of the abdomen as well as an x-ray of the lungs were normal.

#### Treatment

The lesion was excised initially with a small margin. After the histological diagnosis of a leiomyosarcoma, a second resection was performed with a 2-cm margin and removal of the fascia of the underlying muscle. The defect was covered with a free skin graft taken from the flexor side of the right upper arm.

#### Follow-up

One year after surgical resection, there were no signs of a local recurrence or distant metastases.

### RESULTS

#### Histological findings and immunohistochemical characterization

**Hematoxylin & eosin histology.** Light microscopy showed that

Table I. Immunohistological differentiation of spindle-shaped cutaneous tumours

Antibody	Detected tumour
Vimentin	Mesenchymal tumour
Neurofilament protein	Tumours of neural origin
S-100	Neuroectodermal tumour (incl. melanoma)
HMB 45	Melanocytic tumours
Desmin	Myogenic tumours
Actin	Myogenic tumours



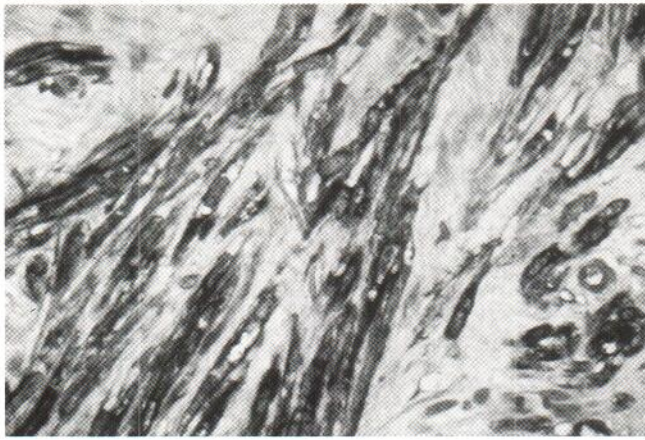


Fig. 2. H&E staining. Cutaneous leiomyosarcoma composed of spindle-shaped cells with blunt-ended nuclei (magnification: 40 $\times$ ).

the tumour had destroyed the middle part of the subcutis and was infiltrating into the speta of the subcutaneous fatty tissue. The border between cutis and subcutis was obscured, and the entire dermis was filled with masses of the tumour. The epidermis covering the tumour was not involved. At higher magnification, spindle-shaped cells were evident with a high degree of cellular and nuclear polymorphism (Fig. 2). Especially in the depth of the tumour, cells fulfilled all criteria of malignancy, and the tumour showed a markedly dense cellularity and the loss of an orderly fascicular pattern.

**Immunohistochemistry (IHC):** In Table I, the differential diagnoses of leiomyosarcomas are listed. Since H&E staining does not allow for a clear differentiation of different spindle-shaped tumour cells, IHC was performed using the APAAP method as described previously (7). Briefly, 4  $\mu$ m sections were cut and stained by the standard APAAP technique (7). Sections were incubated for 30 min with the primary antibody of mouse or rabbit origin. Antibodies used and tumours predominantly detected are listed in Table I. After a short wash, sections were treated with mouse monoclonal antibody anti-rabbit Ig (Dako), diluted 1:200 if necessary, and rabbit anti-mouse (Z 259, Dako), diluted 1:40 for 30 min at room temperature. Sections were then incubated with APAAP complexes (diluted 1:40) for 30 min and stained after a further wash by incubation with new fuchsin substrate for 30 min under continual agitation. Quantitative evaluation was performed by counting all positive cells in ten high-power magnification (100 $\times$ ) fields.

The tumour of our patient was negative for neurofilaments and the melanocytic marker HMB 45. Only a small number of tumour cells showed reactivity with the S-100 antibody. The tumour showed strong activity with antibodies against vimentin and the muscle-specific intermediary filaments actin (Fig. 3) and desmin.

## DISCUSSION

**Clinical features.** Superficial leiomyosarcomas account for about 3–5% of all superficial tissue sarcomas (1, 4, 5, 8–10). There is no sex prevalence (1, 4). The first manifestation can be at any age but is most common between 50–70 years.

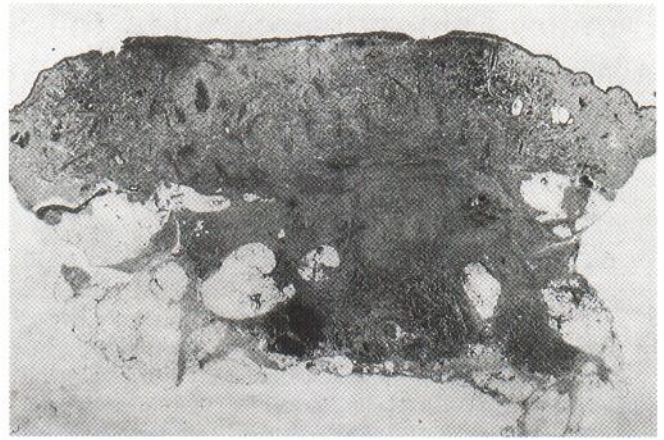


Fig. 3. APAAP staining against muscle specific actin (magnification: 10 $\times$ ).

Cutaneous leiomyosarcomas occur predominantly on the proximal portion of the extremities as solitary lesions with predilection for the hair-bearing extensor surface (1, 3, 5). The diagnosis is rarely made on clinical examination although pain and tenderness are the most frequent symptoms reported by the patients (1, 3–5). The differential diagnoses to be considered are listed in Table I. The occurrence of multiple nodules is rare and should always alert one to the possibility of an internal primary tumour (2).

**Histopathologic and immunohistochemical characteristics.** Histological features of leiomyosarcomas alone may occasionally lead to confusion with other cutaneous spindle-shaped tumours. IHC analysis allows for the diagnosis of leiomyosarcoma. Co-expression of vimentin, desmin and muscle-specific actin represents the characteristic phenotyp of leiomyosarcomas (2).

Leiomyosarcomas are subdivided into dermal and subcutaneous types by their histological localization. Swanson et al. (2) correlate S-100 staining with position of the tumour within the skin. Dermal tumour are supposed to show a diffuse staining pattern whereas deeply infiltrating neoplasias show only focal or no reactivity. The tumour presented here showed strong reactivity with antibodies to vimentin, desmin and ac-

Table II. Summary of criteria for subdividing the dermal and subcutaneous types of leiomyosarcoma, as described in the literature

Dermal type	Subcutaneous type
Clinical parameters:	
Reddish colour	Normal skin colour
Adherent to epidermis	Skin movable
Ulcerated	Skin intact
Tumour less than 2 cm	Tumour more than 2 cm
Slowly growing	Rapidly growing
	Pseudo capsule on histology
Prognosis:	
Local recurrence: 10–30%	up to 50%
Rate of metastases: 10%	30–40%



tin. But only very few tumour cells expressed the S-100 antigen.

*Therapy and prognosis.* In general, cutaneous leiomyosarcomas have a favourable prognosis regarding survival. Wide surgical excision allows for the total removal of the tumour and is the therapy of choice. A close follow-up is recommended for early detection of local recurrences, which develop in a high percentage of patients (Table II) (1, 4, 5, 8). Metastatic spread occurs seldom and appears to be correlated with the depth of the original tumour. It occurs to the regional lymph nodes and hematogeneously to the lungs (1, 4, 11). Therapies other than surgery are difficult to assess. Leiomyosarcomas are reported to be relatively radioresistant (5, 12), but only a very small number have been treated because the tumour is so rare. The same is true for chemotherapy. One attempt to reduce tumour masses by doxorubicin was not successful (5).

## REFERENCES

1. Enzinger FM, Weiss SW, eds. Soft tissue tumours. St. Louis: Mosby, 1988, 402-421.
2. Swanson PE, Stanley MW, Scheithauer BW, et al. Primary cutaneous leiomyosarcoma. A histological and immunohistochemical study of 9 cases, with ultrastructural correlation. *J Cutan Pathol* 1988; 15: 129-141.
3. Stout AP, Hill WT. Leiomyosarcoma of the superficial soft tissues. *Cancer* 1958; 11: 844-854.
4. Jegasothy BV, Gilgor RS, Hull DM. Leiomyosarcoma of the skin and subcutaneous tissue. *Arch Dermatol* 1981; 117: 478-481.
5. Fields JP, Helwig EB. Leiomyosarcoma of the skin and subcutaneous tissue. *Cancer* 1981; 47: 156-169.
6. Russell WO, Cohen J, Enzinger F, et al. A clinical and pathological staging system for soft tissue sarcomas. *Cancer* 1977; 40: 1562-1570.
7. Schadendorf D, Tiedemann KH, Haas N, Czarnetzki BM. Detection of human papillomaviruses in paraffin-embedded condylomata acuminata. *J Invest Dermatol* 1991; 97: 549-554.
8. Stieler W, Mensing H, Schaeg G, Sehn E. Primäres kutanes Leiomyosarkom. *Hautarzt* 1991; 42: 44-47.
9. Braun-Falco O, Kind P, Meister P. Kutanes Leiomyosarkom. *Hautarzt* 1985; 35: 428-429.
10. Ernst TM, Haas N. Kutane Metastase eines retroperitonealen Leiomyosarkoms am Kapillitium. *Akt Derm* 1986; 12: 89-91.
11. Dahl J, Angervall L. Leiomyosarcoma. Study of 47 patients. *Pathol Eur* 1974; 9: 307-314.
12. Phelan JT, Sherer W, Mesa P. Malignant smooth muscle tumours (leiomyosarcoma) of soft tissue origin. *N Engl J Med* 1962; 266: 1027.