

Demodex-attributed Rosacea-like Lesions in AIDS

J. REDONDO MATEO, O. SOTO GUZMÁN, E. FERNÁNDEZ RUBIO and F. DOMÍNGUEZ FRANJO

Department of Internal Medicine, Dermatology and Pathologic Anatomy, General Hospital of Segovia, Spain

The association between AIDS and demodicidosis has been occasionally described elsewhere. We present a new case, in a patient with post-transfusional AIDS, who had many papules and pustules localized to the upper trunk and face, in relation to zidovudine treatment. Key word: *Demodex folliculorum*.

(Accepted May 17, 1993.)

Acta Derm Venereol (Stockh) 1993; 73: 437.

J. Redondo Mateo, Carretera de Avila, s/n, General Hospital Segovia, Spain.

Papular lesions of the face have been described in AIDS patients (1). In some cases they have been associated with *Demodex folliculorum* (2-4). We here present a case of facial papular lesions which could be attributed to AIDS.

CASE REPORT

A 48-year-old woman, with a history of mitral commissurotomy 10 years earlier, and bilateral duct ligation, needed transfusion and prothrombin complex, in relation to severe bleeding. In 1991, 8 years later, she was diagnosed as having posttransfusional AIDS. In October 1992, the patient was treated with digoxin, verapamil, fluconazole and zidovudine, and also permanent acenocumarol. The hematologic findings were: total lymphocytes 1000/mm³; Cd4 (T4) 4.8%; Cd8 (T8) 53.3%; ratio 0.09%. Forty-five days after the treatment with zidovudine, the patient developed many papules, papule-pustules, erythematous lesions, some of them with pustular content, with intense itching localized to face, chin, neck, and the upper thorax (Fig. 1). No systemic or topical treatment with corticosteroids had been given.

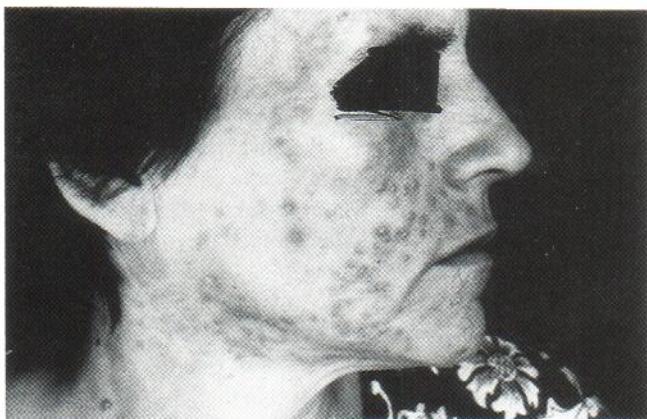


Fig. 1. Papule-pustule lesions in the face and neck.

Bacteriologic (including media for anaerobic and aerobic organisms) and fungus studies were negative. Total lymphocytes were 1900/mm³; Cd (T4) was 3.1%, Cd8 (T8) 63.9% and the ratio Cd4/Cd8 0.05. A biopsy was performed on a papule-pustule from the neck. The hematoxylin-eosin stain showed areas of necrosis of the superficial and deep dermis, with many neutrophils, lymphocytes and histiocytes. In the deep and superficial hair follicles, *Demodex* was observed. In some areas there were multinuclear cells, typical in reactions to foreign bodies. Occasionally the infiltration of the leukocytes reached the epithelium (exocytosis). Neither bacteria nor fungi were observed with Giemsa and PAS stain after pretreatment with diastases. Topical treatment with metronidazole applied twice a day over a period of a month was not successful. Therefore the treatment was changed to crotamiton lotion (Euraxil), again twice a day. There was a complete recovery after a month and a half. No lesions have appeared since the end of the treatment.

DISCUSSION

The role of *Demodex* in human cutaneous pathology has frequently been discussed. It has been suggested that it is only a quantitative problem. It is likely that the changes in humoral and cell-mediated immunity that occur in AIDS patients may lead to the proliferation of commensal mites such as *Demodex*. *Demodex* is able to carry both bacteria and fungi on its body and its bowel (5) and may be a likely mechanism for infection spread. Viruses have also been found in some mites (6), and perhaps *Demodex* can also carry them. The onset of papular lesions in our patient and others (3, 4) a few days after initiation of AZT therapy could suggest a contribution of the immune improvement induced by the drugs to the mechanism of skin disease.

REFERENCES

1. Cockerell C. Cutaneous manifestations of HIV infection other than Kaposi's sarcoma: clinical and histologic aspects. *J Am Acad Dermatol* 1990; 22: 1260-1269.
2. Ashack R, Frost M, Norins A. Papular pruritic eruption of demodex folliculitis in patients with acquired immunodeficiency syndrome. *J Am Acad Dermatol* 1989; 21: 306-307.
3. Dominey A, Rosen T, Tschen J. Papulonodular demodicidosis associated with immunodeficiency syndrome. *J Am Acad Dermatol* 1989; 20: 197-201.
4. Banuls J, Ramon D, Aniz E, Jorda E, Torres V. Papular pruritic eruption with human immunodeficiency virus infection. *Int J Dermatol* 1991; 11: 801-803.
5. Wolf R, Ophir J, Avigad J, Lengy J, Krakowski A. The hair follicle mites (*Demodex* spp.). *Acta Derm Venereol (Stockh)* 1988; 68: 535-537.
6. English F. *Demodex*. A cause of blepharitis in Australia. *Med J Aust* 1969; 1: 1359-1360.