

Lichenoid Eruption Induced by Low Dose Captopril

S. S. WONG, C. C. LONG and P. J. A. HOLT

Department of Dermatology, University Hospital of Wales, Cardiff, Wales, UK

A patient with congestive cardiac failure developed a rash following captopril treatment. The clinical and histological features were consistent with a lichenoid eruption. The rash spontaneously resolved without any treatment three months after captopril was discontinued. Key words: A. C. E. inhibitors; Sulphydryl group; Papules.

(Accepted December 16, 1991.)

Acta Derm Venereol (Stockh) 1992; 72: 358-359.

C. C. Long, Department of Dermatology, University Hospital of Wales, Cardiff, CF4 4XW, Wales, United Kingdom.

Rashes occurring during the first few weeks of treatment have been the commonest of the side effects reported with captopril. Lichenoid eruptions produced by captopril are uncommon. We report the first case of a lichenoid eruption induced by low dose captopril.

CASE REPORT

An 83-year-old woman with long-standing aortic stenosis presented in March 1991 with left ventricular failure and atrial fibrillation. She was treated initially with diuretics and digoxin. Captopril 6.25 mg three times daily was added to her treatment one week later to further control her heart failure. She improved significantly and was discharged on captopril 12.5 mg twice daily. She presented in June 1991 with an itchy rash affecting her arms, upper chest, back and the sides of the neck. Captopril was thought to be cause of the rash, and she was admitted to hospital for monitoring of her heart failure whilst the drug was withdrawn.

Examination at this time revealed multiple violaceous papules and plaques with some scaling on her arms, upper chest, back and neck. There were no blisters or mucosal lesions. A skin biopsy from a papule on the upper chest showed superficial perivascular and interface chronic inflammation with focal disruption of the basal layer with epidermal atrophy. There was patchy hypergranulosis, and necrotic keratinocytes were seen within the epidermis and in the basal layer

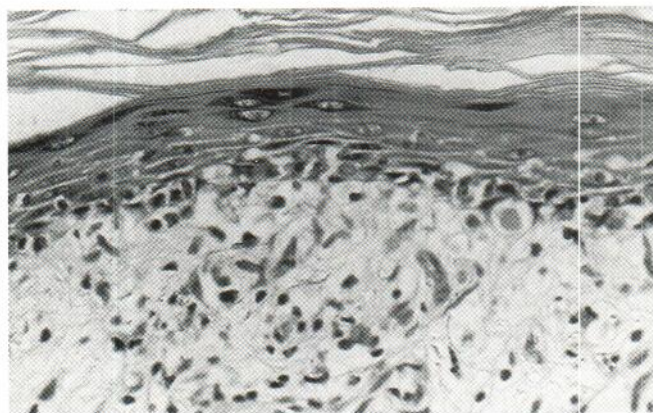


Fig. 1. Skin biopsy of a lichenoid lesion from the upper chest wall showing acanthosis, hyperkeratosis and focal hypergranulosis. Necrotic keratinocytes are present in the lower epidermis and there is basal layer liquefaction.

(Fig. 1). Direct immunofluorescence showed IgG and C3 intraepidermal cytooid bodies with a fibrin band along the dermo-epidermal junction. The rash began to fade within 48 h of stopping the drug. She developed heart failure one week after drug withdrawal and enalapril 5 mg daily was substituted for captopril. There has been no exacerbation or recurrence of the rash, and the rash faded completely 3 months after drug withdrawal.

DISCUSSION

Up to 62% and 15% of patients treated with enalapril and captopril, respectively, were reported to develop a rash during the first few weeks of treatment. (1). Maculopapular, urticarial (2), pityriasis rosea-like (3), erythroderma (4), psoriasisiform (5), lupus erythematosus-like (6) and pemphigus (7) have all been reported with captopril.

Two types of lichenoid eruptions have been described with captopril with different clinical and histological features (8). The first type of lichenoid eruption was preceded by a pityriasis rosea-like rash and was reported in four patients taking low doses of captopril (12.5-100 mg daily) (8, 9), and the rash evolved to leave hyperpigmented macules in two patients and small lichenoid papules in the other two patients before clearing after 1-2 weeks of drug withdrawal. The second type of lichenoid eruption occurred without any preceding rash and consisted of large lichenoid flat-topped papules which coalesced to form plaques. This type of rash was found in three patients taking large doses of captopril (100-450 mg daily), and the rash took 3-6 months to fade completely. The oral cavity was spared in all seven patients described. Our patient had similar clinical and histological features to the second type of lichenoid eruptions but differed in that she was taking a much lower dose of captopril comparatively (25 mg daily). The pathogenesis of captopril-induced lichenoid eruption is not well understood, though the presence of the active sulphhydryl groups of captopril have been suggested to play an important role in the cell-mediated immunological reactions which lead to the development of the rash (10, 11). Our patient required captopril and benefitted from using enalapril though cross sensitivity between these two drugs have been reported (12).

REFERENCES

1. Weber MA. Safety issues during antihypertensive treatment with angiotensin converting enzymes inhibitors. *Am J Med* 1988; 84 (suppl. A) 16-23.
2. Wilkin JK, Hammond JJ, Kirkendall WM. The captopril induced eruption. *Arch Dermatol* 1980; 116: 902-905.
3. Wilkin JK, Kirkendall WM. Pityriasis rosea-like rash from captopril. *Arch Dermatol* 1982; 118: 186-187.
4. Goodfield MJ, Millard LG. Severe cutaneous reactions to captopril. *Br Med J* 1985; 290: 1111.
5. Wolf R, Tamir A, Brenner S. Psoriasis related to angiotensin converting enzyme inhibitors. *Dermatologica* 1990; 181: 51-53.

6. Patri P, Nigro N, Rebora A. Lupus erythematosus like eruption from captopril. *Acta Derm Venereol (Stockh)* 1985; 65: 447-448.
7. Parfrey PS, Clement MI, Vandenburg MJ, Wright P. Captopril induced pemphigus. *Br Med J* 1980; 281: 194.
8. Reinhardt LA, Wilkin JK, Kirkendall WM. Lichenoid eruption produced by captopril. *Cutis* 1983; 31: 98-99.
9. Rotstein E, Rotstein H. Drug eruptions with lichenoid histology produced by captopril. *Austral J Dermatol* 1989; 30: 9-14.
10. Hsiao L, Yoshinaga A, Ono T. Drug induced bullous lichen planus in a patient with diabetes mellitus and liver disease. *J Am Acad Dermatol* 1986; 15: 103-105.
11. Kurumaji Y, Miyazaki K. Tropenin induced lichenoid eruption in a patient with liver disease and positive patch test reactions to drugs with sulfhydryl group. *J Dermatol* 1990; 17: 176-181.
12. Mcfate Smith W, Kulaga SF, Moncloa F, Pingeon R, Walker JF. Overall tolerance and safety of enalapril. *J Hypertension* 1984; 2(suppl 2): 113-117.